TURKFPS

Turkish Journal Of Facial Plastic Surgery

Cilt / Volume:1 | Sayı / Issue:1 | Kasım / November 2020

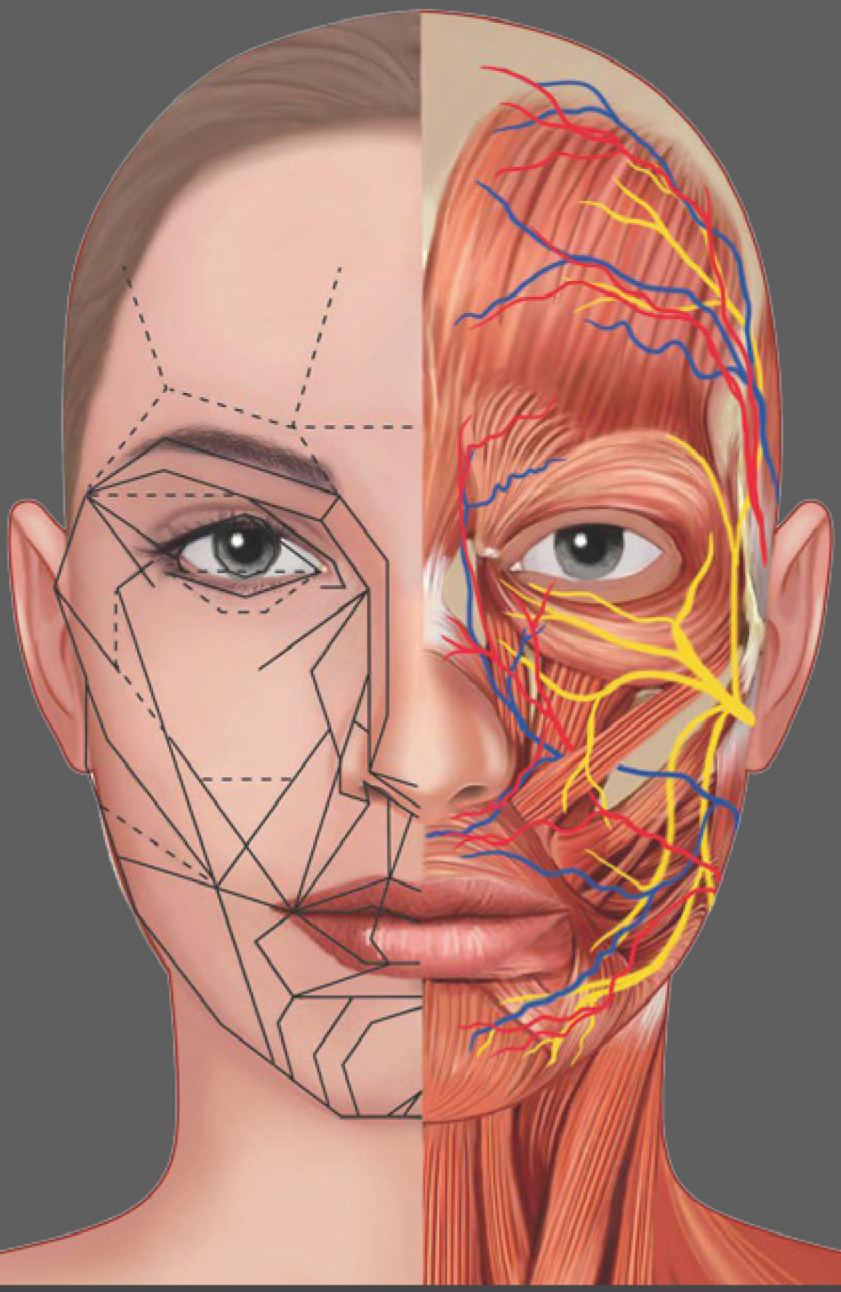

Yılda üç sayı yayımlanır.
Published three times a year.

Yüz Plastik Cerrahi Derneği'nin resmî yayın organıdır.
Official Journal of Facial Plastic Surgery

YÜZ PLASTİK CERRAHİ DERNEĞİ

14. Ulusal Kongresi 1. Sanal Kongresi

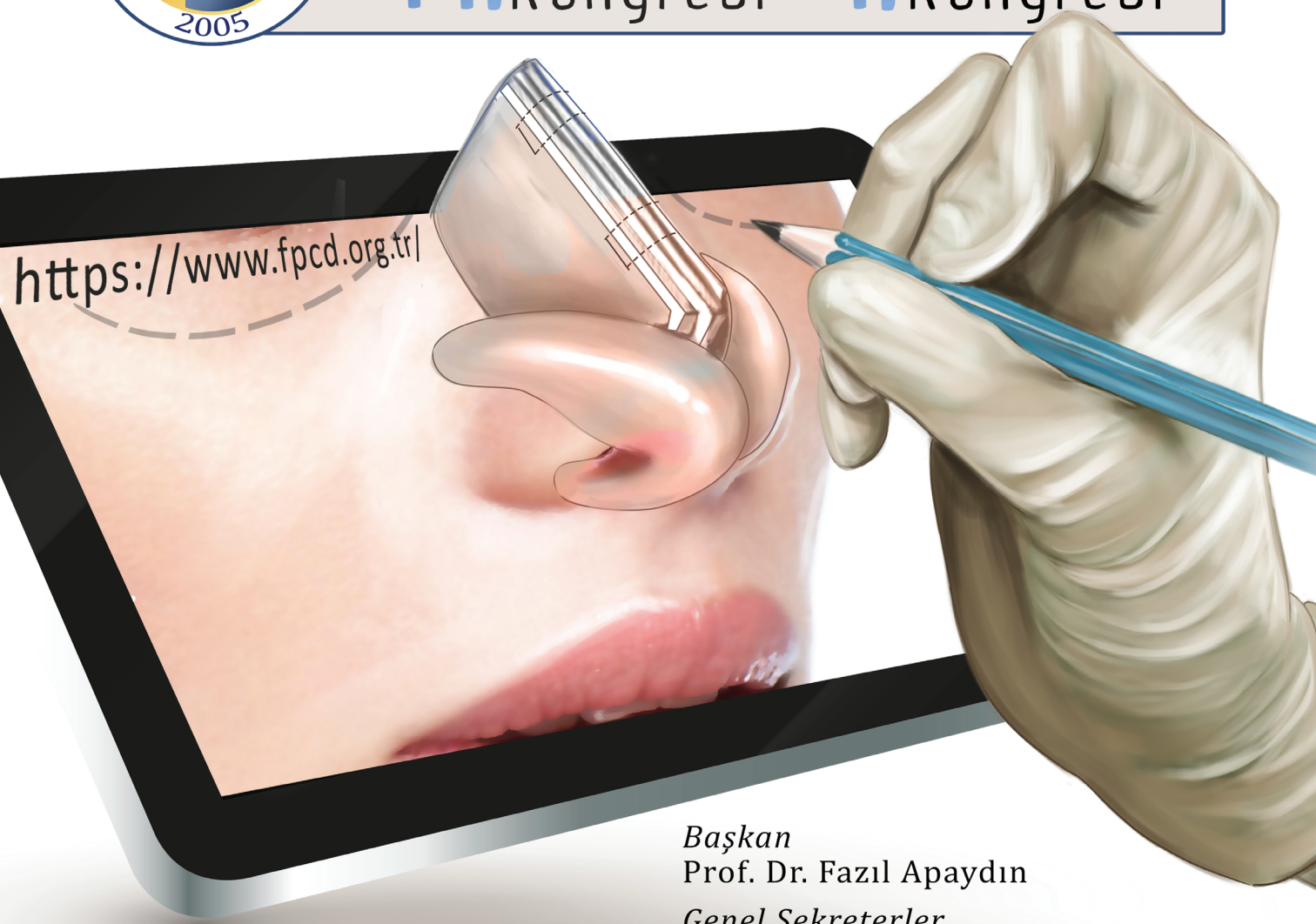

12-13 Aralık 2020

Başkan
Prof. Dr. Fazıl Apaydın

Genel Sekreterler
Doç. Dr. Sercan Göde
Doç. Dr. İsa Kaya

Organizasyon Komitesi

Prof. Dr. Tarık Şapçı
Prof. Dr. Alper Can Çağıcı
Prof. Dr. Tamer Erdem
Prof. Dr. Taşkın Yücel
Prof. Dr. Yusufhan Süoğlu
Prof. Dr. Selçuk İnanlı
Doç. Dr. Eren Taştan
Doç. Dr. Tevfik Sözen

Turkish Journal of Facial Plastic Surgery

Editör
Prof. Dr. Ö. Taşkın Yücel
Hacettepe Üniversitesi Tıp Fakültesi
Kulak Burun Boğaz Anabilim Dalı

Yardımcı Editör
Doç. Dr. Esin Yalçınkaya
Özel Kulak Burun Boğaz Muayenehanesi

Doç. Dr. Gökçe Şimşek
Kırıkkale Üniversitesi Tıp Fakültesi Kulak Burun Boğaz Anabilim Dalı

Sorumlu Yazı İşleri Müdürü
Prof. Dr. Tarık Şapçı
Özel Kulak Burun Boğaz Muayenehanesi

Turkish Journal of Facial Plastic Surgery
Yüz Plastik Cerrahi Derneği'nin resmi bilimsel yayın organıdır.

Sahibi:
Yüz Plastik Cerrahi Derneği

Sorumlu Yazı İşleri Müdürü:
Tarık Şapçı

İletişim Adresi:
Koşuyolu Mahallesi Mahmut Yesari Cad.
No: 25 Kadıköy - İstanbul

E-Mail:
turkjfps@gmail.com

Telefon:
+90 216 428 9551

Tasarım:
Kolhis Medya

E dergi olarak erişime açılmıştır.

ÖNSÖZ

Yüz Plastik Cerrahisi Derneği olarak akademik yönümüzün güçlü, etkin ve üretken olması gerektiğini düşünüyoruz. Günümüzde artık Kulak Burun Boğaz dalının bir alt branşı olan Yüz Plastik Cerrahisi giderek bu konuda yetkinliğini, yaygınlığını artırmak yolunda hızla ilerlemektedir. Akademik çalışmalar bir uzmanlık dalında bilgi birikimini sağlamakta ve bu bilgilerde yapacağımız uygulamaları geliştirip geleceğe ışık tutmaktadır.

Bu yapılan çalışmaların doktorlar ve bu konuda çalışanlar için paylaşılabilmesi için dergilere ihtiyaç bulunmaktadır. Belirli bir analitik sistemle değerlendirilen bu çalışmalar akademik bir süreçten geçirilerek yayınlanmaktadır.

Bu konuda bir ihtiyaç olduğunu düşünerek yüz plastik cerrahisinin yayın organı olarak bu dergiyi çıkarmaya başlıyoruz. Çağdaş ölçülere sahip olan yayınlar yüz plastik cerrahisi ile ilgili olduğu sürece branş ayrımı yapılmaksızın dergimizde yer alacaktır. Bu konuda değerli katkılarınızı bekliyor, en kaliteliye ve en iyiye ulaşmayı amaçlıyarak yola çıkıyoruz.

Bu konuda emeği geçen ve katkı sağlayan herkese teşekkürler.

Prof. Dr. Ö. Taşkın Yücel
Turkish Journal of Facial Plastic Surgery
Dergi Editörü
Kasım 2020

ÖNSÖZ

2001 yılında Türk Kulak Burun Boğaz derneği çatısı altında, sadece rinoplasti ile uğraşan fasiyal plastik cerrahi çalışma grubuyla başlayan yolculuğumuz, 2005 yılında kurmuş olduğumuz Yüz Plastik Cerrahisi Derneği ile devam ederek, 15 yıl içinde çok hızlı bir yükseliş göstermiştir.

Derneğimizin Hamburg'ta düzenlediği taze kadavra kurslarıyla başlayan süreçte; ana derneğimiz çatısı altında açılan Yüz Plastik Cerrahi Okulu ve Avrupa Yüz Plastik Cerrahi Derneği Fellowship programları sayesinde ülkemizde pek çok kalifiye yüz plastik cerrahı yetişmiş ve yetişmeye devam etmektedir. Bugün geldiğimiz nokta da, sevinerek görmekteyiz ki, derneğimiz çatısı altında olan değerli pek çok cerrah, gerek ülkemizde gerekse uluslararası alanda konularında ciddi söz sahibi olmuşlardır.

Uğraşı alanımızın popüleritesi nedeniyle zaman zaman maruz kaldığımız saldırılar karşısında, derneğimiz sadece bilimsel anlamda değil hukuksal anlamda da ciddi mücadeleler vermiş ve vermeye de devam etmektedir. KBB branşının yüz plastik cerrahisiyle ilgili yaptığı tüm işlemlerin, TUKMOS içine girmesiyle birlikte ülkemizdeki tüm eğitim kurumlarında asistanlıkta yüz plastik cerrahi eğitimlerine başlanmış ve bu alanımız için bir milat olmuştur.

Derneğimizin yıllık kongresi, kursları, kadavra ve canlı cerrahi toplantıları yanında, tek eksiği olan bilimsel dergimizi de elektronik ortamda, Prof.Dr.Taşkın Yücel'in editorlüğünde çıkartmış olmanın gururunu yaşıyoruz. Dergimizin de kısa bir süre içinde gerek ülkemizde gerekse uluslararası alanda hak ettiği saygınlığa ulaşabilmesi için hep birlikte çalışmamız gerektiğinin bilinciyle, ülkemizde yüz plastik cerrahisiyle uğraşan tüm meslektaşlarımızın dergimize gerekli yazı desteği vermesini diliyoruz.

Daha nice sayılarda buluşmak dileğiyle...

Prof. Dr. Tarık Şapçı
Yüz Plastik Cerrahi Derneği
Yönetim Kurulu Başkanı
Kasım 2020

DANIŞMA VE DEĞERLENDİRME KURULU
Can Alper Çağıcı
Eren Taştan
Fazıl Apaydın
Selçuk İnanlı
Tamer Erdem
Tarık Şapçı
Taşkın Yücel
Tevfik Sözen
Yusufhan Süoğllu

ULUSLARARASI DANIŞMA KURULU
Alwyn D'Souza
Dean Toriumi
Hesham Saleh
Regan Thomas
Yong Ju Yang

Genel Bilgiler ve Editörler Kurulu Politikası

TJOFPS (Turkish Journal of Facial Plastic Surgery) yazı dili Türkçe ve İngilizce olan Ocak, Mayıs ve Eylül aylarında olmak üzere dört ayda bir, yılda üç kez yayımlanan hakemli bir dergi olup orijinal makale, literatür gözden geçirmeleri, olgu sunumları, teknik bildirileri ve uzman görüşlerini yayınlar. Her makalenin başında yazı başlığı, özet ve "medline" kurallarına göre düzenlenmiş anahtar kelimelerin İngilizceleri verilmektedir.

Tüm yazılar bilimsel katkıları, özgünlükleri ve içerikleri açısından bilimsel komite tarafından bağımsız hakemlik ilkelerine göre değerlendirilir. Derginin editoryal ve yayın süreçleri International Committee of Medical Journal Editors (ICMJE), the World Association of Medical Editors (WAME), the Council of Science Editors (CSE), the Committee on Publication Ethics (COPE), and the European Association of Science Editors (EASE) gibi uluslararası kuruluşların kurallarına uygun olarak şekillenmektedir.

TJOFPS 'de yayınlanan ifadeler ya da görüşler editörler, yayın kurulu ya da yayıncının değil yazar(lar)ın görüş ve bakış açısını yansıtmaktadır; yayınlanan içeriğe ait nihai sorumluluk yazarın kendisine aittir.

Bilimsel ve Etik Sorumluluk

Yazarlar, bilimsel verilerinin doğruluğundan bizzat sorumludurlar. Kişilerin yazarlık hakkını, çalışmaya verdikleri katkıya uygun olarak elde ettikleri kabul edilir.

Yazarlık haklarına riayet etmek, hayalet ve lütuf yazarlığa imkan vermemek için'Yazar Katkı Formu', sorumlu yazar tarafından doldurulmalıdır.

Makalede, bir kitap veya yayında yayımlanmış bir görüntü kullanılması durumunda, yayın sahibi ve yayımlayıcı kurumdan yazılı izin alınması ve gönderim aşamasında söz konusu iznin Yayın Kurulu'na sunulması gerekmektedir.

Üst yazıda, çalışma kapsamında incelenen kişilerden veya yasal vasilerinden 'bilgilendirilmiş onam formu' ("informed consent") ve çalışılan kurumun etik kurulundan 'etik kurul izni' alınıp/alınmadığı veya çalışmada insan deneyleri ile ilgili 1975'te yayımlanan Helsinki Bildirgesi'ne uyulup/uyulmadığı belirtilmeli, varsa aksi durumlar açıklanmalıdır. Deneysel çalışmalar ve ilaç araştırmalarında, Dünya Tıp Derneği "World Medical Association (WMA)" tarafından belirlenen "Declaration of Helsinki-Ethical Principles for Medical Research Involving Human Subjects" ve "Guide for the Care and Use of Laboratory Animals" ile ilgili etik komisyon raporu istenecektir.

Araştırmalara yapılan her türlü yardım ve diğer desteklerin alındığı kişi ve kuruluşlar beyan edilmeli ve çıkar çatışmasıyla ilgili durumları açıklamak amacıyla "International Committee of Medical Journal Editors" (ICMJE) Potansiyel Çıkar Çatışmaları Bildirim Formu doldurulmalıdır.

Telif Hakkı

Yazarlar, yazının değerlendirme aşamasından itibaren, ulusal ve uluslararası yasalar çerçevesindeki her türlü telif hakkını dergiye devreder. Bunun için, tüm yazarlar tarafından imzalanan "Yayın Hakkı Devir Formu", yazının sisteme yüklenmesi aşamasında dergiye ayrıca gönderilmelidir. Yazılarda kullanılan metin, tablo, şekil, resim ve her türlü içeriğin, ulusal ve uluslararası telif haklarına konu olabilecek mali ve hukuki sorumluluğu yazarlara aittir. Yayıma kabul edilen makalenin yayın hakkı, alınan telif hakkı devri doğrultusunda TJOFPS'ye geçer. Daha önce herhangi bir dilde basılmış yazılar dergide basılmak üzere değerlendirilmez. Yazarlar TJOFPS 'ye gönderdikleri bir yazıyı başka bir dergiye gönderemezler. Makalelerde yapılacak tüm değişiklerde yazar ve basımevinin izni alınır.

Üst Yazı

TJOFPS 'ye gönderilecek tüm yazılar, bir "üst yazı" içermelidir. Üst yazıda; iletişim kurulacak yazar(lar)ın adres, telefon, faks numaraları ve e-posta adresleri, yazının aynı zamanda değerlendirilmek üzere başka bir elektronik ya da basılı mecraya gönderilip/gönderilmediği ve daha önce Türkçe ya da başka bir dilde yayımlanıp/yayımlanmadığı belirtilmelidir. Ayrıca, değerlendirme aşamasındaki yazının değerlendirme sürecindeyken başka bir dergiye gönderilmeyeceği bilgisi açıkça vurgulanmalıdır. Hazırlanan yazı, kağıda basıldıktan sonra imzalanmalı ve bu haliyle taranarak .jpg dosyasına dönüştürüldükten sonra sistemimize yüklenmelidir. Daha önce başka bir dergiye gönderilen, ancak yayına kabul edilmeyen yazılar için açıklama yapılmalıdır. Bu yazıların, önceki hakem raporlarının Dergimize gönderilmesi, değerlendirme sürecinin hızlanmasını sağlayacaktır. Toplantılarda sunulan

yazılar için organizasyonun tam adı, tarihi, şehri ve ülkesi belirtilmelidir.

Çevrimiçi Makale Gönderme

Yazılar, A4 kağıdı boyutundaki sayfada, 12 punto, 1.5 satır arası ile Word belgesi (*.doc) olarak hazırlanmalı, turkjfps@gmail.com adresine mail olarak gönderilmelidir.

Bu sistem dışından gönderilen yazılar değerlendirmeye alınmayacaktır. İletişim kurulacak yazarlara, sisteme kayıt olmalarından sonra, kullanıcı adı ve şifre sağlanacaktır. Yazarların, tanımlanan kullanıcı adı ve şifre ile makale gönderme sistemine girmelerinden sonra, sistemin yönlendirici bilgilerini dikkatlice okumaları ve tüm bilgileri eksiksiz kaydetmeleri, gereksiz gecikmeleri önleyecektir. Yazının resim, şekil, tablo ve kaynak gibi eklerinin yanı sıra, "üst yazı", "telif hakkı devir formu", "potansiyel çıkar çatışmaları bildirim formu" ve "etik kurul izin" formları gibi gerekli ek belgeler de aynı anda sisteme yüklenmelidir.

Makalelerin Hazırlanması

Yazıların formatı Dergi kurallarına ve ICMJE tarafından hazırlanan ICMJE-Recommendations for the Conduct, Reporting, Editing and Publication of Scholarly Work in Medical Journals (updated in December 2019- http://www.icmje.org/icmje-recommendations.pdf) kurallarına göre düzenlenmeli, sunumu ise uluslararası kılavuzlara uygun olmalıdır. Randomize çalışmalar CONSORT, gözlemsel çalışmalar STROBE, tanısal değerli çalışmalar STARD, sistematik derleme ve meta-analizler PRISMA, hayvan deneyli çalışmalar ARRIVE ve randomize olmayan davranış ve halk sağlığıyla ilgili çalışmalar TREND kılavuzlarına uyumlu hazırlanmalıdır.

Makale yazımında, Türk Dil Kurumu'nun Bilim ve Sanat Terimleri Sözlüğü ve Tıp Terimleri Kılavuzu gibi kaynaklar kullanılmalıdır. Kısaltmalar, özet ve ana metin içerisinde ayrı ayrı olmak üzere, ilk kullanımda tanımlanmalı ve kısaltma, tanımın ardından parantez içerisinde verilmelidir. Kısaltmaların dilimizde kullanılan şekli tercih edilmelidir (CT yerine BT gibi). Yabancı sözcükler, Türkçe okunuşlarına göre yazılmalıdır. Dergi, gerekli gördüğü yerlerde dil ve yazım ile ilgili uygun düzeltmeleri yapma hakkını saklı tutar. Yazılar, gerekli görüldüğünde düzeltme yapılmak üzere sorumlu yazara geri gönderilebilir.

Dergiye gönderilen yazılar ilk aşamada, Editörler tarafından ön değerlendirmeye alınır. İntihal, kopya ve mükerrer yazım ("duplication") açısından yayın denetimleri de bu aşamada yapılır. Bu türden etik sorunların saptanması durumunda, Committee on Publication Ethics (COPE) kılavuzları çerçevesinde işlem yapılacaktır. Bu aşamaları geçtikten sonra yazı, çift-kör yöntemle seçilmiş en az 2 hakeme gönderilir. Hakemler, yazının konusuyla ilgili uluslararası literatürde yayınları ve atıfları olan bağımsız uzmanlar arasından seçilmektedir. Araştırmalar, sistematik derlemeler ve meta-analiz yazıları ayrıca istatistik kontrolünden geçirilir. Yazarlar, metinde büyük bir değişiklik yapılmaması şartıyla, Editörler tarafından gerekli görülen düzeltmelerin yapılmasını kabul ederler.

Yazılar basıma kabul edildikten sonra yazar sayısında ekleme, çıkarma veya isim sırasında değişiklik yapılamaz.

Başlık Sayfası

Her yazıda başlık sayfası, çevrimiçi ("online") sisteme ayrı bir Microsoft Word dosyası olarak yüklenmeli, yazının Türkçe-İngilizce başlığı, en son akademik dereceleriyle birlikte yazarların tam adları, çalışmanın yapıldığı bölüm, kurum, şehir ve ülke bilgilerini içermelidir. Çalışma farklı kurumlarda gerçekleştirildiyse, yazarların kurumları üst simgeler ile belirtilmelidir. Yazışma adresinde; sorumlu yazarın tam adı, posta ve e-posta adresleri, telefon ve faks numaraları yer almalıdır. Yazının içeriği daha önce herhangi bir sunumun bir parçası olmuşsa toplantının adı, tarihi ve yeri belirtilmelidir. Finansal Destek Beyanı ve Teşekkür bölümleri de bu sayfada yer almalıdır.

MAKALE TİPLERİ

A. Özgün makale

Özet, Giriş, Gereç ve yöntem, Bulgular, Tartışma ve Kaynaklar bölümlerinden oluşur.

Özet

Özgün makalelerin özeti 250 kelimeyi geçmemelidir. Özette yazının amacı, gereç ve yöntem, bulgular ve sonuç bölümleri kısa ve açık olarak verilmeli, özet bölümü yazı okunmadan da yazı hakkında fikir verecek şekilde yapılandırılmalıdır. Tüm makalelerin Türkçe ve İngilizce özeti olmalı yazının İngilizce başlığını da içeren İngilizce özet, ayrıca yazılmalıdır. Türkçe özet Amaç, Gereç ve Yöntem, Bulgular ve Sonuç alt başlıklarını, İngilizce özet ise Purpose, Material and Methods, Results ve Conclusion alt başlıklarını içermelidir.

Anahtar kelimeler
Türkçe ve İngilizce özetlerin altında en az 3, en fazla 5 adet kelime veya tamlama verilmelidir. Kısaltmalar, anahtar kelime olarak kullanılmamalıdır.

Giriş
Bu bölümde, konu birkaç cümle ile anlatılarak en son gelişmeler verilmeli, gereksiz ayrıntılardan kaçınılmalı; bu çalışmayı yapış nedeni ve amacı açık bir şekilde anlatılmalıdır.

Gereç ve yöntem
Çalışılan hasta grupları ya da laboratuvar hayvanları, kullanılan gereçler ve yöntem, çalışma planı, ve kontrol grupları açık ve kısa olarak anlatılmalıdır. Yararlanılan istatistiksel analiz yöntemleri ve etik konularla ilgili izinler yukarıda açıklandığı gibi belirtilmelidir. Bu bölüm, kullanılan yöntemi uygulamak isteyen birisine öğretecek kadar ayrıntılı, okuyucuyu sıkmayacak kadar kısa ve net olmalıdır. Kullanılan ilaçların ve cihazların özgün isimleri ile birlikte üretici firma adı ve üretildiği ülke yazılmalıdır.

Bulgular
İstatistiksel yöntemlerle desteklenmiş bulgular ayrıntılı olarak verilmelidir. Resim, şekil ve tablolar, metin içinde verilen bulguları desteklemeli, ancak tekrar etmemelidir. Verinin, metin, tablo veya şekil formatındaki sunumların bir tanesinde gösterilmesi yeterlidir. Bu bölümde, sadece en önemli bulgular vurgulanmalı, bulgular diğer araştırmalarla karşılaştırılmamalıdır; bu tip karşılaştırmalar tartışma bölümüne saklanmalıdır.

Tartışma
Çalışmanın bulguları, ilgili literatür verileri ile karşılaştırılarak irdelenmeli, önemi ve farkı vurgulanmalıdır. Bu bölümde, çalışmanın eksik yanları açıkça belirtilmeli ve gerekiyorsa sorunun çözümüne yardımcı olacağı düşünülen çalışma önerileri yapılmalıdır. Bulgular bölümünde sunulan detaylar tekrar edilmemeli ve bu bölümünde belirtilmemiş yeni veri sunulmamalıdır. Görüşler sadece çalışmada bulunan gerçeklerle desteklenecek şekilde sınırlandırılmalı, araştırılmayan ya da gösterilemeyen varsayımlar tartışmaya eklenmelidir.

Özgün yazılarda, yazı 18 sayfa veya 4500 kelimeyi, kaynak sayısı 35'i ve resim-grafiklerin sayısı 15'i aşmamalıdır.

B. Derleme
Güncel bir konunun, uzman kişilerce derinliğine incelendiği ve bu kişilerin deneyimlerinin ayrıntılı literatür verileri ile sentezlendiği yazılardır. Bu yazılar, bir konunun klasik bilgi ötesinde zenginleştirilerek yorumlanması şeklinde olmalı ve ilişkili en son yayınlar gözden geçirilerek hazırlanmalıdır. Yazının özeti, alt başlıksız düzenlenmelidir; ana metnin alt başlıkları ise yazarlar tarafından seçilebilir.

Bu tür yazılarda, yazı 15 sayfa veya 4000 kelimeyi, kaynak sayısı 50'yi ve resim-grafiklerin sayısı 20'yi aşmamalıdır.

C. Resimlerle bir konu
Bir konunun, resim ve şekil ağırlıklı olarak sunulmasıdır. Pratikte sık karşılaşılan konular seçilmeli, yazılı bölüm olabildiğince kısa olmalı ve konu eğitici bir şekilde sunulmalıdır. Yazının alt başlıkları, yazarlar tarafından seçilir. Özete gerek yoktur.

Bu tür yazılarda, yazı 4 sayfa veya 1500 kelimeyi, kullanılan kaynak sayısı 15'i ve resim-grafiklerin sayısı 30'u aşmamalıdır.

D. Olgu sunumu
Eğitici değeri olan, ilginç ve nadir görülen olgular seçilmelidir. Ayrı bir sayfada, olgunun neden sunulduğunu ve ana bulgularını içeren, alt başlıksız bir şekilde düzenlenmiş İngilizce bir özet bulunmalıdır; Türkçe özete gerek yoktur. Yazının amacını da içeren kısa bir girişten sonra yorumda, öncelik taşıyan kısa klinik bilgilerle sunuma geçilmeli, tartışma bölümünde olgunun literatür verilerine katkısı vurgulanmalıdır.

Olgu sunumlarının 4 sayfa veya 1500 kelimeyi, kaynak sayısının 8'i ve görüntü sayısının 4'ü aşmaması gerekir.

E. Nasıl yapılır?-teknik bildiri
"Nasıl yapılır?" bölümünde, tanı ve tedavi pratiğinde en çok yapılan işlemler, konunun uzmanı kişilerce anlatılır. Anlatım kısa ve açık olmalı, gerektiğinde çizimlerle desteklenmeli ve kullanılan gereçler açık isimleri ile belirtilmelidir. Bu yazıların başlıca amacı, bu işlemleri yapmak isteyen ilgili uzmanlara yardımcı olmaktır. Genellikle Yayın Kurulu'nun davet ettiği yazarlar tarafından hazırlanır.

F. Tanınız nedir?
Eğitim amacına dönük ilginç olguların açık bir şekilde sunulduğu ve Yayın Kurulu'nun davet ettiği yazarlar tarafından hazırlanan yazılardır.

G. Editöre Mektup
Son bir yıl içinde TJOFPS'de yayımlanan bir yazının önemi, gözden kaçan hatası veya bilinmesi gereken diğer ayrıntılarının vurgulandığı yazılardır. Yazarlar, okurların ilgisini çekebileceğini düşündükleri eğitici olgu ve konular hakkında da editöre mektup gönderebilirler. Okurların konuyla ilişkili, yorum içeren kendi görüşleri de bu bölümde sunulabilir.

Bu tür yazıların, 2 sayfa veya 500 kelimeyi, kaynak ve resim sayısının da 4'ü aşmaması gerekir.

Yazı türleri	Kelime sınırı●	Özet kelime sınırı	Kaynak sınırı	Yazar sınırı	Tablo sınırı	Şekil-resim sınırı
Özgün Makale	4500	400 (yapılandırılmış)	50	6*	4	7 ya da toplam 15
Derleme	4000	200	100	5	4	15 ya da toplam 24
Resimlerle konu	1500	400	20	5	0	15 şekil ya da toplam 30
Olgu sunumu	1500	200	8	5	2	3 şekil ya da toplam 6
Mektup	500	0	4	4	0	2 şekil ya da toplam 4

* Çok merkezli ya da multidisipliner çalışmalarda 6 yazarın üzerinde olabilir.

● Başlık sayfası, kaynaklar; şekil açıklamaları ve tablolar dahil

Kaynaklar

Kaynaklar ayrı bir sayfada, yazı içindeki geçiş sırasına göre 1'den başlanarak dizilmelidir.
"Biomedikal Dergilere Gönderilen Makaleler için Gerekli Standartlar"a uygun hazırlanmalıdır (http://www.amaassn.org/public/peer/wame/uniform.htm). Dergi isimleri "Index Medicus"ta kullanıldığı şekilde kısaltılmalıdır. Yazar sayısının altıyı geçtiği kaynaklar için, ilk üç isim yazıldıktan sonra Türkçe ise "ve ark", yabancı dilde ise "et al" kısaltmaları kullanılabilir.
a. Dergilerde yayımlanan makalelerden yararlanıldığında: Mendelson EB, Bohum-Velez M, Neiman HL. Endometrial abnormalities: evaluation with transvaginal sonography. AJR 1989; 160: 130-137.
b. Kitaplardan yararlanıldığında: Morrow PC, Townsend DE. Synopsis of gynecologic oncology, 3rd. ed. New York: Churchill Livingstone 1987; 159-205.
c. Kitap içerisindeki bölümlerden yararlanıldığında: Hoskins WJ, Perez C, Young RC. Gynecologic tumors. In: DeVita VT Jr, Hellman S, Rosenberg SA, eds. Cancer: principles and practice of oncology. 3rd. ed. Philadelphia: Lippincott, 1989; 1099-1150.

Tablolar

Tablolar ana dosyanın sonunda, kaynak listesinden hemen sonra sunulmalıdır. Yazıda yer verilen tüm tablolara ana metin içerisinde atıf yapılmalı, tablolar atıf sırasına uygun biçimde numaralandırılmalıdır. Her tablo için tablonun içeriği ve amacını belirten açıklayıcı bir başlık kullanılmalı, başlık tablo üzerinde verilmelidir. Tablolarda kullanılan tüm kısaltmalar (ana metin içerisinde tanımlanmış olsalar bile) tablo altında tanımlanmalıdır. Tablolar, Word yazılımının "Tablo Ekle" komutu kullanılarak hazırlanmalı, okunması kolay bir biçimde düzenlemelidir.

Şekiller

Şekiller, grafikler ve fotoğraflar ana dosyaya eklenmemelidir; değerlendirme sürecinde yaşanabilecek aksamaların önlenmesi amacıyla ayrı dosyalar halinde .tiff veya .jpg formatında, yüksek boyut ve çözünürlükte (minimum 300 dpi ve 100x100 mm) çevrimiçi makale sistemine yüklenmelidir. Gri-skalalı görüntüler, en az 600 dpi çözünürlüğe sahip olmalıdır. Şekiller alt birimlere ayrıldığında her alt birim ayrı bir dosya olarak sisteme yüklenmeli, alt birimler tek bir görsel oluşturacak biçimde birleştirilmemelidir. Kalın/ince oklar, yıldızlar vb işaret ve semboller, şekil altyazılarını desteklemek amacıyla kullanılabilir. Yazının geri kalan kısımlarında olduğu gibi şekiller de "kör" hazırlanmalı, yazar, hasta, kurum vb bilgilerini işaret edebilecek tüm bilgiler şekillerin kapsamı dışında bırakılmalıdır.

Şekil altyazıları ana dosyanın en sonunda sunulmalı, şeklin alt birimlere ayrıldığı durumlarda aşağıdaki formatta düzenlenmelidir:

Resim 3. a-d. a. Boston Scientific Flexima Quickstick (8-10 F) trokar kateter, b. Biotech Neo-Hydro (8-10-12-14 F) trokar kateter, c. Uresil (6-8-10-12-14 F) trokar kateter, d. Argon Medical Skater (6-8-10-12-14 F) trokar kateter.

Bilimsel kısaltmalar: Radyasyon ölçümleri ve laboratuvar değerleri "International System of Units (SI)" kullanılarak verilmelidir. Bu birimler sistemi için JAMA 1986; 255: 2329-2339 kaynağına bakılabilir. Kan basıncı mmHg cinsinden verilmeli, cc yerine mL tercih edilmeli, kısaltmaların sonlarına nokta konulmamalıdır.

Diğer

Metinde kullanılan tüm kısaltmalar ana metinde ilk kullanımda tanımlanmalı ve kısaltma tanımı parantez içinde verilmelidir.

İstatistiksel analiz tıbbi dergilerin raporlama istatistik kurallarına uygun olarak yapılmalıdır (Altman DG, Gore SM, Gardner MJ, Pocock SJ. Statistical guidelines for contributors to medical journals. Br Med J 1983: 7; 1489–1493.). Çalışmanın istatistiksel analiz süreci ile ilgili bilgiler ana metin içinde belirtilmelidir.

Ana metin içerisinde yer alan ilaç, ürün, donanım ya da yazılımın adı üreticileriyle birlikte aşagıdaki

formatta belirtilmelidir: "Discovery St PET/CT scanner (GE Healthcare)."

Yararlanılan kaynak, tablo ve şekiller metin içerisindeki yerlerine atfen sıralanarak numaralandırılırlar.

Düzeltmeler

Gelen yazıların, konuyla ilgili ve deneyimli hakemlerce değerlendirilmesi sonrasında gerektiğinde başvurdukları düzeltme talepleri ve eleştiriler, iletişim adresi belirtilen yazara gönderilir. Basımın gecikmemesi için istenen düzeltmeler, en kısa zamanda cevaplandırılmalıdır. Düzeltmelerin cevapları ile birlikte en geç 30 gün içinde tarafımıza gönderilmesi gerekmektedir. 30 günden sonraya kalan düzeltmelerde, editörler kurulu makaleyi geri çevirme hakkını saklı tutar. Düzeltmelerde, tüm hakemlerin görüşlerine ayrı ayrı cevap yazılmalı ve yapılan düzeltmelerin sayfa numarası ile satır sırası belirtilmelidir. Yapılan tüm değişikliklerin metin üstünde koyu olarak belirtildiği bir kopya ile düzeltmeler yapıldıktan sonraki son halinin temiz bir kopyası birlikte gönderilmelidir. Sunulan kaynakların ve verilerin doğruluğundan yazarlar sorumludur. Hatalı, aldatıcı veya yanlış yönlendirici bilgilerin varlığı fark edildiğinde, "baş editör" makaleyi yayımdan çekme ve bunu duyurma hakkına sahiptir.

Overview

The TJOFPS (Turkish journal of Facial Plastic Surgery), published three times a year (January, May and September), publishes original peer-reviewed articles, reviews, case reports, technical reports and commentaries in the fields of colon and rectum in English and Turkish languages. The title, abstract, and key words (according to medical subject headings) are provided in English and in Turkish at the beginning of each article.

Editorial and publication processes of the journal are shaped in accordance with the guidelines of the international organizations such as the International Committee of Medical Journal Editors (ICMJE), the World Association of Medical Editors (WAME), the Council of Science Editors (CSE), the Committee on Publication Ethics (COPE), and the European Association of Science Editors (EASE).

Statements or opinions expressed in the manuscripts published in TJOFPS reflect the views of the author(s) and not the opinions of the editors, the editorial board, or the publisher; the editors, the editorial board, and the publisher disclaim any responsibility or liability for such materials. The final responsibility in regard to the published content rests with the authors.

Ethical standards

For studies involving human or animal participants, the authors should indicate whether the procedures followed were in accordance with the ethical standards of the responsible committee on human and animal experimentation (institutional or regional) and with the Helsinki Declaration (JAMA 2000; 284:3043–3049). Application or approval number/year of the study should also be provided. The editorial board will act in accordance with COPE guidelines if an ethical misconduct is suspected.

It is the authors' responsibility to carefully protect the patients' anonymity and to verify that any experimental investigation with human subjects reported in the submission was performed with informed consent and following all the guidelines for experimental investigation with human subjects required by the institution(s) with which all the authors are affiliated with. For photographs that may reveal the identity of the patients, signed releases of the patient or of his/her legal representative should be enclosed.

Prospective human studies require both an ethics committee approval and informed consent by participants. Retrospective studies require an ethics committee approval with waiver of informed consent. Authors may be required to document such approval.

In the event of alleged or suspected research misconduct, e.g., plagiarism, citation manipulation, and data falsification/fabrication, the Editorial Board will follow and act in accordance with COPE guidelines.

Copyright Transfer

TJOFPS requires each submission to be accompanied by a Copyright Transfer Form. By signing the copyright agreement, the authors hand over the copyright of their work to TJOFPS. In the case of a rejection decision, copyright of the manuscript will be returned to the authors.

Authorship

Each individual listed as an author should fulfill the authorship criteria recommended by the International Committee of Medical Journal Editors (ICMJE - www.icmje.org). To be listed as an author, an individual should have made substantial contributions to all four categories established by the ICMJE: (a) conception and design, or acquisition of data, or analysis and interpretation of data, (b) drafting the article or revising it critically for important intellectual content, (c) final approval of the version to be published, and (d) agreement to be accountable for all aspects of the work in ensuring that questions related to the accuracy or integrity of any part of the work are appropriately investigated and resolved. Individuals who contributed to the preparation of the manuscript but do not fulfill the authorship criteria should be acknowledged in an acknowledgements section, which should be included in the title page of the manuscript. If the editorial board suspects a case of "gift authorship", the submission will be rejected without further review.

TJOFPS requires authors to submit an Authorship Contributions Form during the initial submission which is available for download through the journal's web page.

Declaration of Conflict of Interest

TJOFPS requires and encourages the authors and

the individuals involved in the evaluation process to disclose any existing or potential conflicts of interests including financial,consultant, institutional, and other relationships that might lead to bias or a conflict of interest. Each contributing author isrequired to electronically fill in the ICMJE Form for Disclosure of Potential Conflicts of Interest (available at www.icmje.org) andthe forms must be submitted during the initial submission.

Online Article Submission

Articles, on A4 paper size page, 12 point, 1.5 Word document should be prepared as (* .doc) between the lines and sent to turkjfps@gmail.com.

Manuscript Preparation

Manuscripts should be prepared in accordance with the ICMJE - Recommendations for the Conduct, Reporting, Editing and Publication of Scholarly Work in Medical Journals (updated in December 2019 – available at www.icmje.org).

Original Investigations and Reviews should be presented in accordance with the following guidelines: randomized study – CONSORT, observational study – STROBE, study on diagnostic accuracy – STARD, systematic reviews and meta-analysis PRISMA, nonrandomized behavioral and public health intervention studies – TREND.

Manuscripts are evaluated and published on the understanding that they are original contributions, and do not contain data that have been published elsewhere or are under consideration by another journal. Authors are required to make a full statement at the time of submission about all prior reports and submissions that might be considered duplicate or redundant publication, and mention any previously published abstracts for meeting presentations that contain partial or similar material in the cover letter. They must reference any similar previous publications in the manuscript.

Authors must obtain written permission from the copyright owner to reproduce previously published figures, tables, or any other material in both print and electronic formats and present it during submission. The original source should be cited within the references and below the reprinted material.

Cover letter: A cover letter must be provided with all manuscripts. This letter may be used to emphasize the importance of the study. The authors should briefly state the existing knowledge relevant to the study and the contributions their study make to the existing knowledge. The correspondent author should also include a statement in the cover letter declaring that he/she accepts to undertake all the responsibility for authorship during the submission and review stages of the manuscript.

Title page: A separate title page should be submitted with all manuscripts and should include the title of the manuscript, name(s), affiliation(s), and major degree(s) of the author(s). The name, address, telephone (including the mobile phone number) and fax numbers and e-mail address of the corresponding author should be clearly listed. Grant information and other sources of support should also be included. Individuals who contributed to the preparation of the manuscript but do not fulfill the authorship criteria should also be acknowledged in the title page. Manuscripts should not be signed by more than 6 authors unless they are multicenter or multidisciplinary studies.

Main document

Abstract: All submissions (except for Letters to the Editor) should be accompanied by an abstract limited to 400 words. A structured abstract is only required with original articles and it should include the following subheadings: PURPOSE, METHODS, RESULTS, CONCLUSION.

Main points: Each submission should be accompanied by 3 to 5 "main points", which should emphasize the most striking results of the study and highlight the message that is intended to be conveyed to the readers. As these main points would be targeting residents, experts and residents of other fields of medicine, as well as experts, they should be kept as plain and simple as possible. These points should be constructed in a way that provides the readers with a general overview of the article and enables them to have a general idea about the article.

The main points should be listed at the end of the main text, above the reference list.

Example: Liu S, Xu X, Cheng Q, et al. Simple quantitative measurement based on DWI to objectively judge DWIFLAIR mismatch in a canine stroke model. Diagn Interv Radiol 2015; 21:348–354.

• The relative diffusion-weighted imaging signal intensity

(rDWI) of ischemic lesions might be helpful to identify the status of fluid attenuated inversion recovery (FLAIR) imaging in acute ischemic stroke.
• The relative apparent diffusion coefficient (rADC) value appears not useful to identify the status of FLAIR imaging in the acute period.
• Based on our embolic canine model, rDWI increased gradually in the acute period, while the rADC kept stable, which might explain why rDWI is helpful to identify the status of FLAIR imaging, while rADC is not

Main text

Original Articles

Original articles should provide new information based on original research. The main text should be structured with Introduction, Methods, Results, and Discussion subheadings. The number of cited references should not exceed 35 and the main text should be limited to 4500 words. Number of tables included in an original article should be limited to 4 and the number of figures should be limited to 7 (or a total of 15 figure parts).

Introduction

State briefly the nature and purpose of the work, quoting the relevant literature.

Methods

Include the details of clinical and technical procedures. Research ethics standards compliance.
All manuscripts dealing with human subjects must contain a statement indicating that the study was approved by the Institutional Review Board or a comparable formal research ethics review committee. If none is present at your institution, there should be a statement that the research was performed according to the Declaration of Helsinki principles (www.wma.net/e/policy/b3.htm). There should also be a statement about whether informed consent was obtained from research subjects.

Results

Present these clearly, concisely, and without comment. Statistical analysis results should also be provided in this section to support conclusions when available.

Discussion

Explain your results and relate them to those of other authors; define their significance for clinical practice. Limitations, drawbacks, or shortcomings of the study should also be stated in the discussion section before the conclusion paragraph. In the last paragraph, a strong conclusion should be written.

Review Articles

Review articles are scientific analyses of recent developments on a specific topic as reported in the literature. No new information is described, and no opinions or personal experiences are expressed. Reviews include only the highlights on a subject. Main text should be limited to 4000 words and the number of cited references should not exceed 75. Number of tables included in a review article should be limited to 4 and the number of figures should be limited to 15 (or a total of 30 figure parts).

Pictorial Essay

This is a continuing medical education exercise with the teaching message in the figures and their legends. Text should include a brief abstract; there may be as many as 30 figure parts. No new information is included. The value of the paper turns on the quality of the illustrations. Authors can submit dynamic images (e.g. video files) or include supplemental image files for online presentation that further illustrate the educational purpose of the essay. Maximums: Pages of text – 4 (1,500 words); References – 15; Figures – 15 or total of 30 images; No table
Main text should be limited to 1500 words and the number of cited references should not exceed 15. No tables should be included and the number of figures should be limited to 15 (or a total of 30 figure parts).

Technical Notes

Technical note is a brief description of a specific technique, procedure, modification of a technique, or new equipments. It should include a brief introduction followed by Technique section for case reports or Methods section for case series, and Discussion is limited to the specific message, including the uses of the technique, equipment, or software. Literature reviews and lengthy descriptions of cases are not appropriate. Main text should be limited to 1500 words and the number of cited references should not exceed 8. Number of tables included in a technical note should be limited to 4 and the number of figures should be limited to 3 (or a total of 6 figure parts).

Letter to the Editor and Reply

Letters to the Editor and Replies should offer objective and constructive criticism of published articles within last 6 months. Letters may also discuss matters of

general interests and may include images. Material being submitted or published elsewhere should not be duplicated in letters.
Main text should be limited to 500 words and the number of cited references should not exceed 4. No tables should be included and the number of figures should be limited to 2 (or a total of 4 figure parts).

Type of manuscript	Word limit	Abstract word limit	Reference limit	Author limit	Table limit	Figure limit
Original Article	4500	400 (Structured)	50	6*	4	7 or total of 15 images;
Review Article	4000	200	100	5	4	15 or total of 24 images
Pictorial Essay	1500	400	20	5	No tables	15 figures or total of 30 figure parts
Technical Note	1500	200	8	5	2	3 figures or total of 6 figure parts
Letter	500	N/A	4	4	No tables	2 figures or total of 4 figure parts

**Multicenter or multidisciplinary studies should be signed by more than 6 authors*

References

References should be numbered consecutively in the order they are referred to within the main text and all references listed in the reference list should be referred to within the main text in parenthesis. Style and punctuation of each reference in the reference list should be in accordance with the examples listed below;

Standard journal article: Journal titles should be abbreviated in accordance with journal abbreviations used in Index Medicus (for journal abbreviations consult List of Journals indexed for MEDLINE published annually by NLM at http://www.nlm.nih.gov/tsd/serials/lji.html). When there are six or fewer authors, all authors should be listed. If there are seven or more authors, first 3 should be listed, followed by "et al.". A list of authors should be followed by the full title of the article, journal title, year, volume, and page numbers.

Example: Dollinger M, Beyer LP, Haimerl M, et al. Adverse effects of irreversible electroporation of malignant liver tumors under CT fluoroscopic guidance: a single-center experience. Diagn Interv Radiol 2015; 21:471–475.
Epub ahead of print articles: Abboud S, Raparia K, Ubago JM, Resnick S. AngioVac extraction of intraatrial hepatoma masquerading as PICC-associated thrombus. Diagn Interv Radiol 2015 DOI: 10.5152/dir.2015.15243. Published online 28 October 2015.

Books:

Chapter in a book: Hull RD, Hirsh J. Comparative value of tests for the diagnosis of venous thrombosis. In: Bernstein EF, ed. Noninvasive diagnostic techniques in vascular disease. 3rd ed. St. Louis: Mosby, 1985; 779–796.
Personal author(s): Watanabe M, Takeda S, Ikeuchi H. Atlas of arthroscopy. 2nd ed. Tokyo: Igaku Shoin, 1969; 57–59.

Editor (s), compiler(s) as author: Norman IJ, Redfern SJ, eds. Mental health care for elderly people. New York: Churchill Livingstone; 1996.

Tables

Tables should be included in the main document and should be presented after the reference list. Tables should be numbered consecutively in the order they are referred to within the main text. A descriptive title should be provided for all tables and the titles should be placed above the tables. Abbreviations used in the tables should be defined below by footnotes (even if they are defined within the main text). Tables should be created using the "insert table" command of the word processing software and they should be arranged clearly to provide an easy reading. Data presented in the tables should not be a repetition of the data presented within the main text but should be supporting the main text.

Figures and figure legends

Figures, graphics, and photographs should be submitted as separate files (in TIFF or JPEG format) through the submission system. The files should not be embedded in a Word document or the main document. When there are figure subunits, the subunits should not be merged to form a single image. Each subunit should be submitted separately through the submission system. Images should not be labelled (a, b, c, etc.) to indicate figure subunits. Thick and thin arrows, arrowheads, stars, asterisks, abbreviations and similar marks can be used on the images to support figure legends. Like the rest of the submission, the figures too should be blind. Any information within the images that may indicate an individual or institution should be blinded. The minimum resolution of each submitted figure should be 300 DPI. To prevent delays in the evaluation process all submitted figures should be clear in resolution and large in size (minimum dimensions, 100×100 mm).

Figure legds should be listed at the end of the main document.

General

All acronyms and abbreviations used in the manuscript should be defined at first use, both in the abstract and in the main text. The abbreviation should be provided in parenthesis following the definition.

Statistical analysis should be performed in accordance with guidelines on reporting statistics in medical journals (Altman DG, Gore SM, Gardner MJ, Pocock SJ. Statistical guidelines for contributors to medical journals. Br Med J 1983: 7; 1489–1493.). Information on the statistical analysis process of the study should be provided within the main text.

When a drug, product, hardware, or software mentioned within the main text product information, the name and producer of the product should be provided in parenthesis in the following format: "Discovery St PET/CT scanner (GE Healthcare)."

All references, tables, and figures should be referred to within the main text and they should be numbered consecutively in the order they are referred to within the main text.

Revisions

When submitting a revised version of a paper, the author must submit a detailed "Response to reviewers" that states point by point how each issue raised by the reviewers has been covered and where it can be found (each reviewer's comment followed by the author's reply and line numbers where the changes have been made) as well as an annotated copy, and a clear copy of the main document.

Revised manuscripts must be submitted within 30 days from the date of the decision letter. If the revised version of the manuscript is not submitted within the allocated time, the revision option will be automatically cancelled by the submission system. If the submitting author(s) believe that additional time is required, they should request an extension before the initial 30-day period is over.

İÇİNDEKİLER / TABLE OF CONTENTS

1 OPERATIVE PHOTOLOG IN RHINOPLASTY
Fazıl Apaydın 16

2 OUTCOMES OF COMBINED PUSH DOWN WITH HIGH STRIP RESECTION AND BONY CAP DRILLING PROCEDURE
Fetih Furkan, Şahin Göksel Turhal, Sercan Göde 20

3 AESTHETIC ANALYSIS OF THE IDEAL EYEBROW SHAPE AND POSITION: A COMPARISON BETWEEN CELEBRITIES AND NORMAL POPULATION
Esin Yalçınkaya, Özgür Avinçsal, Denizhan Dizdar, Cemal Cingi 26

4 EVALUATION OF THE EFFECTS OF SURGICAL ASSISTED MAXILLARY EXPANSION ON THE INCISIVE CANAL
Neşet Akay, Umut Tekin, Ercüment Önder, Doruk Koçyiğit, Fethi Atıl 32

5 REVİZYON RİNOPLASTİ KOMPLİKASYONU: KOLUMELLA NEKROZU
Burak Mustafa TAŞ, Gökçe ŞİMŞEK, Ercan Akbay, Burak Erden, Rahmi Kılıç 40

OPERATIVE PHOTOLOG IN RHINOPLASTY

Fazıl Apaydın[1]
[1]Ege University School of Medicine, Department of Otorhinolaryngology, İzmir, Turkey

ABSTRACT

The main reason why rhinoplasty is accepted as the most difficult operation in facial plastic surgery is the numerous variations and pathologies of the nose that can be encountered. Although these conditions and the surgical maneuvers can be recorded on a diagram, it is not enough. In this study, a professional photographer equipped with the professional photo cameras has taken at an average of 175 pictures during each surgery from 2007 to 2014. The main advantages of this approach were found to give better chances for follow-up, self-assesment, education and medicolegal situations.

Key words: photography, rhinoplasty, photolog

ÖZET

Rinoplastinin yüz plastik cerrahisinin en zor ameliyatı olarak kabul edilmesinin nedeni burunda mevcut sayısız varyasyon ve deformitenin olmasıdır. Ameliyat sırasında karşılaşılan anatomik durum, patolojiler ve uygulanan cerrahinin tüm aşamaları bir diagrama kaydedilebilmesi yararlı olmakta, ancak yeterli olmamaktadır. Bu çalışmada uygun fotoğraf çekim cihazları ve bir profesyonel fotoğrafçı yardımıyla 2007-2014 yılları arasında her ameliyatta ortalama 175 fotoğraf çekilmiştir. Bu işlemin en önemli yararları takip, kendini değerlendirme, eğitim ve adli açıdandır.

Anahtar Kelimeler: fotoğrafçılık, rinoplasti, fotolog

Corresponding Author: Prof. Dr. Fazıl Apaydın

Adress: Ege University School of Medicine, Department of Otorhinolaryngology, İzmir, Turkey
Email address: fazil.apaydin@gmail.com

Introduction

Rhinoplasty is the most common and the most difficult operation in facial plastic surgery. Although there are certain surgical steps in rhinoplasty, every nose is different because each nose has its own anatomic variations, and the surgical plan and techniques used can be different for each individual nose. This reality brings the need to record intraoperative data very seriously. The usual follow-up is done by using consultation notes, operative record, pre- and postoperative pictures. Although a detailed operative record and graphic drawings are very helpful, it is the author's opinion that this is not always enough and intraoperative pictures are usually needed. The aim of this study is to present a method which will enable the surgeon a useful way to gain more information during surgery and keep it with the patient records.

When one looks at the dictionary , two relevant meanings of "log" are found: First "the full nautical record of a ship's voyage and the full record of a flight by an aircraft", second " a record of performance, events, or day-to-day activities". In today's world it is more often used for record keeping. In the world of Internet a web log is called as blog and it is a type of website or part of a website. Most blogs are primarily textual, although some focus on art (art blog), photographs (photoblog), videos (video blogging), music (MP3 blog), and audio (podcasting). In this study I blended the "photo" with "log" and called it as "photolog" meaning that the photos are used to record data during a procedure.

Materials and method:

Seventy patients operated by the author from 2007-2014 at a tertiary referral center and a private hospital were taken into this study. All patients were informed before the surgery that intraoperative pictures would be taken and an informed consent was also taken. The operations lasted from 2 to 5 hours depending on the difficulty of the case. All patients were operated under general anesthesia and a professional photographer was always in the operating room to take the pictures. The photographer was usually located at the right side of the surgeon in order to simulate the surgeon's eye whereas additional multiple views, such as lateral, basal or sky views were also taken.

All the pictures were taken by using a digital SLR camera (Nikon D200 and Nikon D700), 105 mm macro lens (Nikon AF micro Nikkor 105 mm f/2.8D) and a dual strobe flash (Nikon speedlight SB-29s). This equipment enabled a uniform shadowless exposure within a certain distance (approximately 30-50 cm) from the patient's nose. The photographer was asked to shoot during every surgical maneuver. The number of pictures taken changed from 65 to 366 (average 175) depending on the number of techniques employed during surgery (Figure 1). In the beginning, the surgeon has always asked the photographer when and from where to shoot. Although the photographer had connaisence with surgery in time, the surgeon kept on acting as the photographic director of the operation. The pictures were all transferred into the computers and backup disks.

Results:

All the pictures were reviewed after surgery. The quality of the pictures were found to be good to excellent. Although the redundant and noninformative pictures were usually deleted, the number did not come under 40. When the patients have come for the follow-up, these pictures were used to recall the steps employed during the surgery. The high quality pictures of 70 patients covered 6 GB space. These pictures were used for many purposes:

1. Follow-up: It was much easier for the surgeon to remember the surgical steps after evaluating the intraoperative pictures.

2. Self-assessment: The surgeon could see the operative condition clearly and the effect of all the surgical maneuvers for the individual patient could be evaluated.

3. Education: These pictures were all used for educational purposes. The author, the residents and visiting physicians have been doing a briefing for the rhinoplasty patients on a bimonthly basis. All the pre-, per- and postoperative pictures of the patients have been presented and discussed with the residents and visiting physicians.

4. Medico-legal reasons: It is not possible to make every patient happy with rhinoplasty since it has a physchological aspect as well. Sometimes these patients can be very demanding and critical with the result of the surgery. In that case, the use of intraoperative pictures can be very helpful to explain the situation to the patient or to another collegue. This method has been used in one dissatisfied patient which made him believe that the surgeon had done his best for him.

Discussion:

A picture is worth to thousand words. The author has been taking pictures in many operations and videos in some. In earlier times, it was the surgeon himself, a resident, an anestesiologist, a technician or a nurse who was taking the pictures by using different point-and-shoot digital cameras. Altough the resultant pictures were usually satisfactory, they were sometimes not good enough to give information and the number of pictures were usually not sufficient. It was also a very time consuming procedure because the surgeon had to either change gloves each time or spend some additional time for taking pictures. It was also tiresome trying to make a resident, anesthesiologist, nurse or a techician understand how to take a picture. In order to increase the quality of the pictures and stop loosing information and time two things have been done: 1) A professional photographer was hired, 2) Professional photographic equipment was purchased. The photographer was trained in taking studio and intraoperative pictures for facial plastic surgery procedures. The other important factors in photodocumentation is the surgeon's desire, patience and artistic skill in directing and allowing the photographer to take pictures. The harmony of the surgeon and the photographer gives the best results. After these efforts, the quality of the pictures became close to ideal and the loss of intraoperative information has been prevented. Besides, as the coordination of the surgeon with the photographer increases by time, then the photographer is not needed to be supervised. This make the surgeon to concentrate on his operation while quality pictures are taken by the photographer. As can be seen, a lof of time and money should be spent for informative high quality intraoperative pictures. Is it worthwhile? This is a difficult question to answer and almost each individual surgeon has a different answer and perspective for this question. After all these years working with a professional photographer in facial plastic surgery procedures, the author believes that it is one of the most versatile investments for a facial plastic surgeon which always pays back in time.

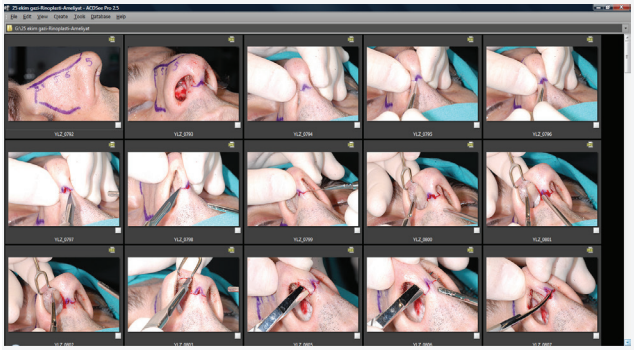

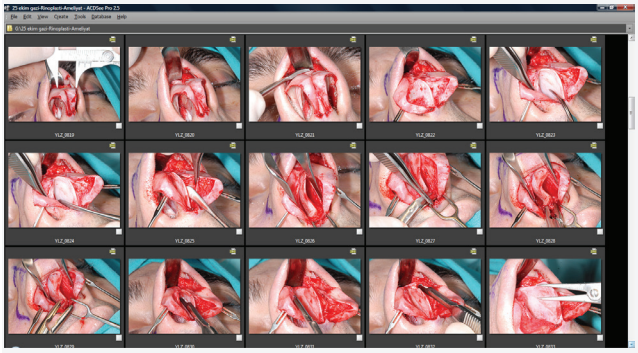

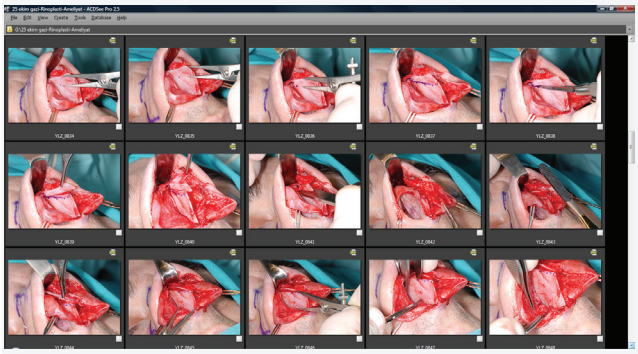

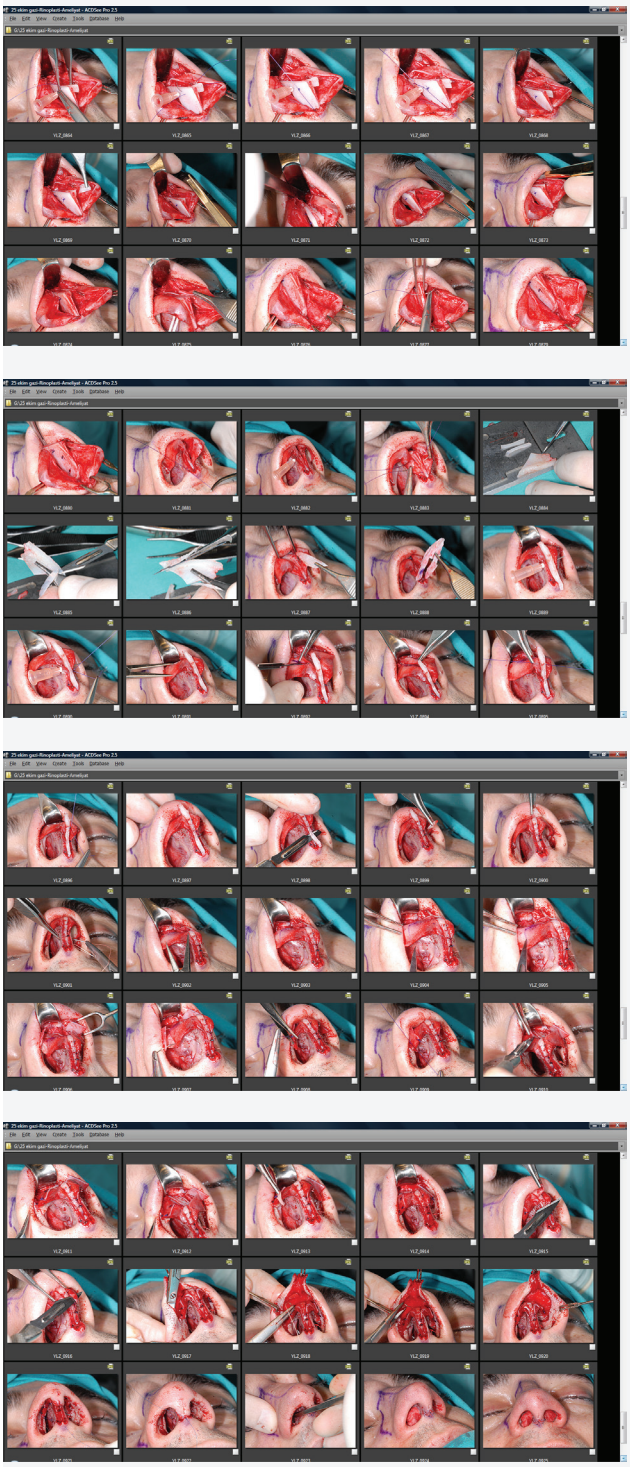

Figure 1: An example of photolog. The photographer has taken many pictures for each step during surgery while the surgeon has been operating. The result is that the surgeon can easily remember what he has done during surgery including every small detail of the operation.

References :

1. http://www.merriam-webster.com/dictionary/log

2. http://en.wikipedia.org/wiki/Log

Combined push down and bony cap drilling procedure

OUTCOMES OF COMBINED PUSH DOWN WITH HIGH STRIP RESECTION AND BONY CAP DRILLING PROCEDURE

Fetih Furkan Şahin[1] Göksel Turhal, Sercan Göde
[1]Ege University School of Medicine, Department of Otorhinolaryngology, İzmir, Turkey

ABSTRACT

Failure to properly repair the middle vault can lead to both functional and aesthetic complaints. Bony or cartilaginous irregularities can be observed after destructive procedures and bone reduction by manual rasping. In the present study the combination of cartilage push down and bony cap drilling has been described and the aesthetic outcomes had been analysed. This prospective study included 67 patients who underwent primary open technique septorhinoplasty between January-July 2019. Preoperative and postoperative sixth-month photographic analyzes and FACE-Q questionnaires were performed in all patients. At the end of the 6-month follow-up period, 15 patients had complains of a wide dorsum. Although 4 patients had mild hump recurrence, none of these requested a revision surgery. Nasal axis deviation was not observed in any patient. Combined "bony cap drill" and "cartilage push-down" technique provides a controlled repair and dorsum reduction, preserves functional structures, and maintains bony dorsum stability especially in crooked noses. In addition, undesired irregularities can be prevented by drilling and reshaping the bony dorsum and cap. However, it should be kept in mind that cartilage push down technique might cause a wide dorsum appearance in the middle one-third of dorsum especially in patients with higher hump.

Key words: Dorsum Preservation Septorhinoplasty; Hump Resection; Septorhinoplasty Complications

ÖZET

Septorinoplastide orta nazal çatının uygun şekilde onarılmaması hem fonksiyonel hem de estetik yakınmalara yol açabilir. Orta nazal çatıdaki kartilaj yapıya yönelik destrüktif müdahaleler ve kemik çatıdaki hump rezeksiyonun rasp ile kontrolsüz uygulanması halinde dorsumda ele gelen düzensizlikler oluşabilmektedir. Bu çalışmada, kartilaj çatı konturlarını ve fonksiyonel ünitelerini koruyan "kartilaj push-down" tekniği ve kemik çatıda da "tur ile redüksiyon" tekniği ile dorsum redüksiyonunun sonuçları sunulmaktadır. Bu prospektif çalışmaya ocak-temmuz 2019 tarihleri arasında primer açık teknik septorinoplasti uygulanan 67 hasta dahil edildi. Tüm hastaların preoperatif ve postoperatif 6. ay dönemlerinde fotoğraflar analizleri yapıldı ve FACE-Q anketleri uygulandı. 6 aylık takip süreci sonunda, 15 hastada geniş dorsum görünümü yakınması gözlendi. 4 hastada hafif derecede hump rekürrensi gözlenmekle birlikte bu hastalarda revizyon cerrahi beklentisi mevcut değildi. Bu çalışmada tanımlanan "kartilaj push-down" ile birlikte "tur ile kemik çatı redüksiyonu" kombine tekniğinin, kontrollü bir onarım ve dorsum redüksiyonu sağlamakta olduğu, fonksiyonel yapıları koruduğu, özellikle eğri burunlarda kemik çatı stabilitesini koruduğu görülmüştür. Ayrıca, kemik çatıda tur kullanımı ile kontrollü redüksiyon sağlaması sayesinde istenmeyen düzensizlikler önlenebilmektedir. Ancak daha yüksek humpa sahip hastalarda kartilaj push down tekniğinin postoperatif dönemde orta 1/3'te geniş dorsum görünümüne sebep olabileceği akılda tutulmalıdır.

Anahtar Kelimeler: Dorsum Koruyucu Septorinoplasti; Hump Rezeksiyonu; Septorinoplasti Komplikasyonları

Corresponding Author: Fetih Furkan Şahin, MD[1]

Adress: Ege University School of Medicine, Department of Otorhinolaryngology İzmir, Turkey
Email address: fetihfurkansahin@gmail.com

Introduction

Hump removal of the both bony and cartilaginous dorsum is possibly one of the most performed steps during septorhinoplasty. Dorsal hump removal improves the profile view. In the meantime, surgeon wants to preserve the natural profile of the nasal dorsum. The cartilaginous middle vault has a unique structure formed by the two upper lateral cartilages and the septal cartilage. This cartilage framework has also an intimate relation with bony septum and nasal bones (1). In classic rhinoplasty, nasal cartilaginous dorsum is cut into three independent pieces and then these pieces are repaired after hump resection. Also, dorsum resection causes the open-roof deformity which has to be repaired afterwards. Even though bony dorsum is repaired, there can be palpable irregularities on nasal dorsum. Both using rasp and osteotomy may cause irregularities on bony dorsum. Possible instability of the lateral nasal wall is another concern. In order to overcome these problems and to preserve nasal dorsum, many techniques have been described. Conventional hump resection is seem to be a hallmark of rhinoplasty. Despite the success of resection techniques in reduction of a dorsal hump and improving the profile view, recent studies suggest that dorsal resection should be replaced by preservation techniques (2). Although dorsum preservation is a current issue in rhinoplasty, the idea and its evolution are not new. In 1914, Lothrop defined the subdorsal resection of septal cartilage and ethmoid bone combined with a transverse osteotomy at the radix to allow for descent of the bony pyramid (3). Cottle described and popularized the cartilage push down technique against resection rhinoplasty (4, 5). This technique aims to keep nasal dorsum intact while reducing the dorsal hump. Another advantage of this technique is preserving the patency of internal nasal valve and avoiding its collapse. As an alternative of rasp for bony dorsum reduction Becker et al have reported their experiences on using powered instruments such as drill in 1997 (6). The nasal dorsum drill offers a precise reduction of dorsal hump by avoiding bony irregularities and sharp edges.

The aim of this article is to discuss the results of combined procedure of push down with high septal strip resection and bony cap drill with cylindrical burr, and analyse the aesthetic outcomes of this combined technique.

Materials and Method

This study was designed as a prospective clinical trial between January and July 2019 in one tertiary academic center. This study was also carried out in concordance with international ethical standards and the World Health Organisation Helsinki Declaration. It was approved by the institutional review board. Informed consent was obtained from all of the subjects.
Sixty-seven patients with primary septonasal deformity over the age of 18 were included in this study. The patients with any severe septal deviation type such as caudal border fracture, vertical septal fracture, subluxation, saddling, the patients without dorsal hump and revision cases were excluded. The patients with mild simple septal deviation were not excluded from the study. All the patients underwent primary open technique rhinoplasty. All cases were operated by the same senior surgeon. The final decision on whether to perform a combined push down and bony cap drill technique or a conventional resection dorsal hump removal were made once the dorsum is fully exposed via an open approach. Those who underwent combined technique were included in this study. All patients were followed-up at least 6 months, up to 1 year.

Outcome Measures

Nasal length, radix height, middle vault dorsum height, bony width, middle vault width, alar flare, columellar height were measured and evaluated through photographic analysis. Also, FACE-Q questionnaire for both functional and aesthetic outcomes were implemented to all patients. Turkish version of FACE-Q questionnaire was used in this study (7). FACE-Q consists 10 questions on a scale from 1 (very dissatisfied) to 4 (very satisfied). According to FACE-Q, higher score indicates better outcome. As well as the preoperative evaluation, photographic analysis and FACE-Q questionnaire were performed for all patients at the postoperative sixth month.

Surgical Procedure

This surgical procedure is mainly originated from the technique that described by Ishida et al. (8). Surgery is initiated with a mid columellar inverted-V incision

and followed by limited degloving. At the level of lower and middle thirds of nasal dorsum, a subperichondrial dissection is performed. Then, bony dorsum is dissected in subperiosteal plane. After dorsum dissection, the cartilage framework is separated by using semi-sharp elevator from the junction with nasal bones. The separation is included the cephalic edge of the upper lateral cartilages. Also, cartilaginous septum is freed from bony septum anteriorly. However, it is very important to keep the cephalic ligament attachments of "septal T" to the reduced bony cap while pushing the cartilage framework down. Upper lateral cartilages are not separated from the quadrangular septal cartilage. Thus, "septal T" form is preserved. Then, a high-septal strip is resected just below the dorsal segment of quadrangular cartilage. A portion of ethmoid bone is either removed (triangular wedge) or cut longitudinally. Conjoined upper and lower remaining parts of cartilaginous septum are secured by through-and-through suturing with 5/0 PDS (polydioxanone suture). If a cartilaginous hump still exists, additional septal strips can be resected. A vertical chondrotomy is performed to the attic side of the cartilaginous septum towards the dorsal line of cartilaginous hump as Neves described (9). After this step, cartilaginous hump is pushed down onto the inferior portion of cartilaginous septum. With this move, the cartilaginous framework is re-positioned posteriorly. In the next step, dorsal bony cap is carefully drilled by 8-mm cylindrical diamond burr. While drilling, cold saline irrigation is used to avoid thermal damage. This bony "de-capping" is performed as an osteoplasty in order to reduce the bony hump and create smooth bony edges. Transverse osteotomy with 2 mm chisel and lateral osteotomies with 6 mm guarded chisel are performed to push down the bony pyramid.

Statistical Analysis

Statistical analysis was made using computer software (SPSS version 22.0, SPSS Inc. Chicago, IL, USA). Chi-square (X2) exact tests were used for the comparison of categorical data while Wilcoxon and Mann-Whitney U tests were used for the analysis of non-parametric variables based on the distribution pattern of the data. Data were expressed as "mean (standard deviation; SD)", percent (%), minimum-maximum, Odds Ratio (OR); 95% confidence interval (CI) and "median (Interquartile range; IQR)" where appropriate. $p<0.05$ was considered statistically significant.

Results

Forty-four patients (65.7%) were female and 23 patients (34.3%) were male. The mean age was 29.6±4.4 years (ranged between 22 and 45 years). The mean follow-up duration was 9.5 months (ranged between 6 and 12 months). Response rates of FACE-Q questionnaires were 100% for both preoperative and postoperative evaluations. The mean preoperative FACE-Q score of all patients was 18.6 and the mean postoperative score was 36.6. The mean postoperative FACE-Q score was significantly better than the mean preoperative score ($p<0.05$).

However, 15 patients (22.3%) out of 67 which had a hump with 4 mm or higher, responded the "the width of your nose (from nasal to nasal)" item of FACE-Q questionnaire poorly than expected. Among all patients, the mean preoperative and postoperative scores of "the width of your nose (from nasal to nasal)" item were 2.8 and 3, respectively and there was no significant difference between pre and postoperative scores ($p>0.05$). However, postoperative scores specific to "the width of your nose (from nasal to nasal)" item were worse than the preoperative scoring for those 15 patients who had a dorsal hump with 4 mm or higher preoperatively. Additionally, in the postoperative photographic analysis, a partial recurrence of dorsal hump was observed in 6 patients (8.9%). However, these 6 patients had no complaints about their postoperative appearance. Figure 1 shows the preoperative and postoperative sixth month appearance of a patient who had complaint of wide middle one-third of the nose and wide alar flare.

Two patients (3%) underwent a revision (alar base reduction) surgery after a six-month follow-up duration. Dorsal camouflage techniques were not required in any cases. None of the patients had a nasal axis deviation or a tip ptosis postoperatively.

Discussion

The middle one-third of the nasal vault has important aesthetic and functional roles. Integrity of upper lateral cartilages and septal cartilage forms the internal nasal valve angle which is the narrowest part of the

nasal airway. Splitting this unique structure may cause functional and aesthetic problems. Reducing the bony hump with rasp or osteotomy may lead some early or late term problems such as focal bony irregularities or open-roof deformity. Since rasp is a traumatic tool, using rasp inattentively may cause harm the keystone area and upper lateral cartilages.

Due to various difficulties of reconstructing the disturbed keystone area and bony dorsum, dorsal preservation rhinoplasty has become a significantly trending subject in rhinoplasty (10, 11). First Lothrop in 1914 and then Cottle in 1946 suggested and developed the idea of dorsal preservation rhinoplasty (3, 4). For many years, various dorsum preservation techniques were performed, however without wide acceptance (12, 13). Later, Saban introduced his cartilage push down approach with high septal strip resection in 2002 (14). Ishida and colleagues reported that this technique may lead to an undesirable wide dorsum and alar flare (8). Recently, Robotti and colleagues described trimming of the lateral "bone-upper lateral cartilage" junction for reshaping the wide or asymmetric middle vault in broad dorsum cases after push down procedure (15). In this present clinical trial, we experienced that the higher nasal hump exists, the more extensive high septal strip removal is required. The outcomes of this study show that the push down technique with high septal strip resection causes wide dorsum and alar flare, if the patient has 4 mm or higher dorsal hump. Therefore, push down technique with high septal strip resection procedure should be avoided for cases with 4 mm or a higher dorsal hump. Nevertheless, none of the patients had a complaint of nasal obstruction, as an advantage of cartilaginous push down technique in this case series. It is also reported that the lack of control while pushing down the cartilaginous dorsum may cause a residual hump due to the spring back effect (15).

The recurrence of a dorsal hump with preservation rhinoplasty is an important long-term complication. Ishida et al. reported a 15% rate of partial hump recurrence in mid-level septal strip resection cases (8). Saban reported a lower hump recurrence rate (3.4%) and suggested that keeping the subdorsal part of cartilaginous septum prevents the shape of the dorsum from changing (16). Tuncel who performed subdorsal resection technique reported a 12% rate of hump recurrence in a series of 520 cases (17). In this series of 67 patients, the senior author performed high septal strip resection and hump recurrence rate was found to be 8.9%. Additionally, the authors of this study experienced that the residual hump appearance is mostly observed in supratip area. In this technique, upper lateral cartilages are not shortened and lowered so, caudal portions of these undisturbed upper lateral cartilages may cause a bulging in supratip area. Obviously, larger humps have much more risk for hump recurrence. Therefore, a let down procedure could be considered instead of push down procedure for cases with higher or larger hump.

In the last decades, powered instruments such as cylindrical diamond burr or piezo-osteotomy has gained popularity among rhinoplasty surgeons. Manual rasp obscures direct visualization of bony structures. On the other hand, drilling with cylindrical burr or piezo-osteotomy allows a better visualization of the bony dorsum. Moreover, powered instruments are less traumatic in experienced hands (6). In our experience, drilling with cylindrical diamond burr allows controlled, fast and effective osteoplasty and decreases irregularities of the bony dorsum. In this case series, the drill was used for osteoplasty alone or was combined with transverse and lateral osteotomies. Palhazi and colleagues suggested the "bony cap" term instead of bony hump (1). Since the cartilaginous hump is covered by a thin bone, they approved the removal of this "bony cap" that can reveal the cartilaginous hump beneath the cap. This "bony cap" reduction by drilling reduces the bony pyramid irregularities after rhinoplasty and allows the exposure of the whole cartilaginous hump and framework. Bony cap drilling with cylindrical diamond burr may also provide a shorter surgery time and faster recovery period with safer postoperative outcomes. Mostly, dorsal hump is not isolated to the cartilaginous dorsum and both cartilaginous and bony dorsum reduction is required. Drilling the "bony cap" is mostly sufficient for bone reduction. In cases with a thick "bony cap" or a high bony dorsal hump, a let down procedure is usually performed with the essential low-to-low lateral and transverse osteotomies (18). Combining high septal strip push down technique with bone drilling is very safe, quick, and has satisfying

cosmetic and functional outcomes. From a functional perspective, this approach allows to avoid the disturbance of internal nasal valve area. Preserving the cartilaginous dorsum and reducing the bony cap with drilling in a controlled manner provide with a satisfactory aesthetic appearance especially for those patients with thin skin and small to medium hump. Preoperative photographic analysis enables the surgeon to measure the dorsal hump height and allows to predict the height of high septal strip to be resected. Regarding this technique, it is important to choose the proper nose for surgery by a careful preoperative photographic analysis. Because this technique may broaden the nose slightly. Therefore, undesired postoperative outcomes can be observed with the cartilaginous push down technique in patients with high or large hump. On the other hand, drilling with cylindrical diamond burr has some benefits such as osteoplasty and smoothing the bony edges after osteotomies. The main limitation of this study is the absence objective functional outcome measures. In addition to patient-reported outcome measures such as FACE-Q, postoperative functional outcomes of the technique can be evaluated by objective anatomic measurements such as acoustic rhinometry or rhinomanometry. Relatively shorter follow-up duration is another limitation of this study. Surely, longer follow-up period could provide more valid outcomes.

Conclusion

In conclusion, the authors of this study suggest that the patients with a broad dorsum or high hump (>4 mm) are not appropriate candidates for the push down procedure with high septal strip resection. Hump recurrence rate is lower in high septal strip resection technique due to preserving the subdorsal portion cartilaginous strut however, it should be kept in mind that let down procedure should be preferred instead of push down technique for higher humps. Besides, bony cap drilling is highly recommended compared to manual rasping. This combined technique provides quick and safe dorsum reduction and preservation.

References

1. Palhazi P, Daniel RK, Kosins AM. The osseocartilaginous vault of the nose: anatomy and surgical observations. Aesthetic surgery journal.2015;35(3):242-251.

2. Daniel RK. The preservation rhinoplasty: a new rhinoplasty revolution. Aesthet Surg J. 2018;38(2):228–229.

3. Lothrop OA. An operation for correcting the aquiline nasal deformity; the use of new instrument; report of a case. Boston Med Surg J. 1914;170:835-837.

4. Cottle MH, Loring RM. Corrective surgery of the external nasal pyramid and the nasal septum for restoration of normal physiology. Ill Med J. 1946;90:119-135.

5. Cottle MH. Nasal roof repair and hump removal. AMA Arch Otolaryngol. 1954;60(4):408-414.

6. Becker DG, Toriumi DM, Gross CW, Tardy ME. Powered instrumentation for dorsal reduction. Facial plastic surgery.1997;13(04):291-297.

7. Gode S, Ozturk A, Sahin M et al. Turkish Validation of the Standardized Cosmesis and Health Nasal Outcomes Survey. Facial Plast Surg.2019;35(04): 397-399.

8. Ishida J, Ishida LC, Ishida LH, Vieira JC, Ferreira MC. Treatment of the nasal hump with preservation of the cartilaginous framework. Plast Reconstr Surg 1999;103(6):1729-1733.

9. Neves JC, Tagle DA, Dewes W et al. The split preservation rhinoplasty:"the Vitruvian Man split maneuver". Eur J Plast Surg.2020;1-11.

10. Rohrich RJ, Muzaffar AR, Janis JE. Component dorsal hump reduction: the importance of maintaining dorsal aesthetic lines in rhinoplasty. Plast Reconstr Surg.2004;114(5):1298–1308.

11. Afrooz PN, Rohrich RJ. The keystone: consistency in restoring the aesthetic dorsum in rhinoplasty. Plast Reconstr Surg.2018;141(2):355–363.

12. Huizing EH. Push-down of the external nasal pyramid by resection of wedges. Rhinology 1976;13:185–190.

13. Pinto RM. On the "let-down" procedure in septorhinoplasty. Rhinology.1997;35(4):178–180.

14. Saban Y, Braccini F, Polselli R (2005) Morphodynamic anatomy of the nose. In: Saban Y, Braccini F, Polselli R, Micheli-Pellegrini V (eds) Rhinoplasties, vol 2002. The monographs of CCA group. n°32, Paris, pp 25–32.

15. Robotti E, Chauke-Malinga NY, Leone F. A Modified Dorsal Split Preservation Technique for Nasal Humps with Minor Bony Component: A Preliminary Report. Aesthetic plastic surgery.2019;43(5):1257-1268.

16. Saban Y, Daniel RK, Polselli R, Trapasso M, Palhazi P. Dorsal preservation: the push down technique reassessed. Aesthet Surg J. 2018;38(2):117–131.

17. Tuncel U, Aydogdu O. The probable reasons for dorsal hump problems following let-down/push-down rhinoplasty and solution proposals. Plast Reconstr Surg. 2019;144(3):378e–385e.

18. Gerbault O, Rollin KD, Palhazi P, Kosins A. Reassessing surgical management of the bony vault in rhinoplasty. Aesthet Surg J.2018;38(6):590–602.

AESTHETIC ANALYSIS OF THE IDEAL EYEBROW SHAPE AND POSITION: A COMPARISON BETWEEN CELEBRITIES AND NORMAL POPULATION

Esin Yalçınkaya[1], Özgür Avinçsal[2], Denizhan Dizdar[3], Cemal Cingi[4]
[1]Private Otorhinolaryngology Clinic, Ankara, Turkey
[2]Taksim Education and Research Hospital, Otorhinolaryngology Clinic, İstanbul, Turkey
[3]Medical Park Bahçelievler Hospital, Otorhinolaryngology Clinic, İstanbul, Turkey
[4]Osmangazi University, Otorhinolaryngology Clinic, Eskişehir, Turkey

ABSTRACT

Objective: To compare the eyebrows of celebrities and fashion models who are widely regarded as attractive with those of selected volunteers to identify clinically useful criteria for achieving attractive eyebrows.
Methods: Full-face frontal photographs of 50 fashion models and celebrities were compared with those of 50 randomly selected volunteers in terms of eyebrow shape (Westmore criteria) and position (McKinney criteria). Six different measurements were used to assess the morphological differences. We also compared male and female participants in terms of eyebrow shape and position.
Results: We found no significant differences between the celebrities and volunteer groups in terms of the Westmore criteria ($p>0.05$). In contrast, eyebrow shape was significantly different between male and female volunteers (Westmore parameters A–B, $p=0.007$; B–C, $p=0.016$ and D–E, $p=0.000$). The assessment of eyebrow position (McKinney criteria) revealed that the mean pupil-brow distance (G-H) was significantly greater for celebrities than volunteers (female: $p=0.031$ and male: $p=0.001$) and for female than male ($p=0.007$, female: 2.56 cm, male: 2.23 cm, IPD standardized) and mean brow-hairline distance (F-G) of celebrities was greater than volunteers and females was greater than males (female: 6.19 cm, male: 5.87 cm, IPD standardized).
Conclusions: Corresponding results states that wide forehead and higher pupil-brow distances are considered more attractive. When female and male ratios are compared brow apex is located in a higher location in females. Similarly females has wider forehead, their horizontal brow lengths are shorter and pupil brow distances are longer.

Key Words: Eyebrow, beauty, facial aesthetics, celebrities and models

ÖZET

Amaç: Dünyaca ünlü ve etkileyici kabul edilen modeller ile gönüllülerin kaş şekil ve pozisyonları karşılaştırılarak, klinik olarak kullanışlı olabilecek etkileyici kaş kriterlerini belirlemek.
Gereç ve Yöntem: Dünyaca ünlü modellerden oluşan grup (n=50) ile aynı cinsiyet ve benzer yaşlardaki gönüllülerin (n=50) tam yüz frontol fotoğraflarındaki kaş şekilleri 'Westmore Kriterleri', kaş pozisyonları ise 'McKinney Kriterleri' temel alınarak karşılaştırıldı. Morfolojik farklılıkları ortaya koymak için altı farklı ölçü kullanıldı. Ayrıca kadın ve erkek katılımcılar arasında da kaş şekil ve pozisyonu karşılaştırıldı.
Bulgular: Westmore kriterlerine göre, ünlüler ve gönüllüler arasında anlamlı fark saptanmadı ($p>0.005$). Ancak, kaş şekli kadın ve erkeklerden oluşan gruplar arasında anlamlı olarak farklıydı (Westmore parametreleri; A–B, $p=0.007$; B–C, $p=0.016$, D–E, $p=0.000$). Kaş pozisyonu değerlendirilmesinde ise (McKinney kriterleri) ünlülerde gönüllülere göre ortalama kaş-pupil mesafesi (G-H) anlamlı olarak (kadın: $p=0.031$, erkek: $p=0.001$) fazladır, kadınlarda da erkeklere göre anlamlı olarak fazladır ($p=0.007$, kadınlarda: 2.56 cm, erkeklerde: 2.23 cm, IPD oranlanmış). Ayrıca ortalama kaş-saç çizgisi mesafesi (F-G) ünlülüde gönüllere göre fazladır, kadınlarda da erkelere göre fazladır (kadınlarda: 6.19 cm, erkeklerde: 5.87 cm, IPD oranlanmış).
Sonuç: Geniş bir alın ve yüksek kaş-pupil mesafesi kadın ve erkeklerde daha etkileyici kabul edilmektedir. Kadınlar ve erkekler karşılaştırıldığında ise, kadınlarda kaş apeksi erkeklere göre daha yüksek yerleşimlidir. Yine kadınlar daha geniş alına sahiptir, yatay kaş uzunlukları daha kısadır ve pupil-kaş mesafeleri daha yüksektir.

Anahtar Kelimeler: Kaş, güzellik, yüz estetiği, ünlüler ve modeller

Corresponding Author: Esin Yalçınkaya
Adress: Private ENT clinic, Ankara, Turkey Email address: esinkbbesin@gmail.com

Introduction

Eyebrows play an essential role in facial expressions and aesthetics [1]. People focus on the area around the eyes during a conversation and when looking at pictures of faces; therefore, improvements in this area have the most significant impact on attractiveness. Moreover, ptosis of the lateral brow is a common sign of aging. Thus, an understanding of the ideal aesthetic facial proportions is crucial for obtaining the desired surgical outcome and avoiding an unnatural appearance, patient dissatisfaction and complications. Several procedures have been developed to modify and improve the aesthetic appearance of the eyebrows, and numerous investigators have attempted to define the shape and position of the ideal brow. However, the notion of what constitutes an attractive eyebrow is influenced by culture, ethnicity, current fashion trends and the views of the patient, observer and surgeon. Furthermore, the surrounding periorbital features affect eyebrows appearance, suggesting that the ideal eyebrow shape differs by face shape. Thus, the criteria for the ideal eyebrow shape remain a controversial subject among cosmetic surgeons.

Previous studies have investigated patients' desired eyebrow shape, [2] measured the positions of landmarks around the eyebrows [3] and compared changes in the perception of a beautiful face over decades [4]. Given the increasing trend towards eyebrow surgery for aesthetic reasons, and the lack of a consensus about what constitutes the ideal eyebrow shape, we compared the eyebrows of celebrities and fashion models who are widely regarded as attractive with those of randomly selected volunteers to identify useful criteria for achieving an aesthetic eyebrow.

Methods

We enrolled 50 randomly selected subjects (15 males, 35 females) from Ankara, Turkey who were between the ages of 18 and 55 years. Written informed consent was obtained from all volunteers, and the study was approved by the ethics committee of our institution. Exclusion criteria included any upper facial surgery, facial trauma or neuromotor disorders, any treatment involving a dermal filler or neurotoxin within the previous 12 months, a previous brow lift, and eyebrows that had been tweezed or waxed within the last 30 days.

Standardized full-face frontal photographs were taken of the volunteers with their eyebrows in a natural position, at a distance of 1 meter using a D80 digital camera with a 28–105-mm lens and a Speedlight SB600 camera-mounted flash all Nikon, Tokyo, Japan.
Online databases were searched between 2010 and 2017 for photographs of male and female celebrities and fashion models considered to be attractive (Table 1) [5-54], and 50 full-face frontal images were obtained (15 male, 35 female). The images met the following inclusion criteria: (1) estimated age of between 16 and 57 years (both sexes) at, (2) lips close and at rest and (3) no shadow on the face. The photographs were downloaded from the internet and compared with the volunteers' facial pictures.

The distance measurements alone will give a certain value without the consideration of the face size and image size. In the process of comparing a measurement value for a bigger face vs. a smaller face or two images with different image sizes, the values cannot give enough information because the difference is expected. However facial proportions can produce statistically significant data since all the measurements can be evaluated in comparison to the size of the face. Therefore prior to measurements a standardization process is used. The interpupillary distance's (IPD) in the images are proportioned to give certain values (female, 7.34 cm; male, 7.32 cm) by changing the size of images in order to have similar face sizes. After IPD held constant for all images measurements were made in the same manner for both the volunteer and celebrity/fashion model photographs. Those IPDs (female, 7.34 cm; male, 7.32 cm) which are used as standard values, are the mean values of the volunteers' IPDs obtained depending on the photography method and image size. The values are in the range of a similar adult group's IPD range given in the paper [55]. For the rest of the paper all the measurement values are actually the result of real distances divided by the individuals IPD and multiplied by the standard IPD values in cm, and referenced as "IPD standardized".

The landmarks were selected for the linear and angular measurements (Fig 1,2). Six different measurements of the eyebrow were analyzed according to Westmore [56] and McKinney's [57] proposals as follows:

1. The distance from the medial aspect of the eyebrow to the ala (A-B),
2. The distance between the medial and lateral ends of the brow (B-C),
3. The distance between the lateral end of the brow and ala (A-C),
4. The distance between brow apex and lateral limbus (D-E),
5. The distance of forehead (F-G)
6. The distance between midpupil and the top of the brow (G-H),
(Figure 1, 2).

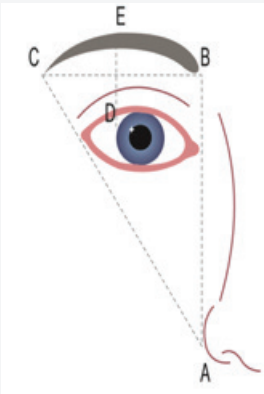

***Figure 1**: Westmore Criteria*

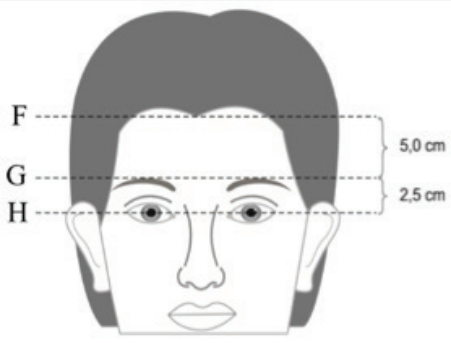

***Figure 2:** McKinney Criteria*

Statistical Analysis: Statistical analysis was performed by SPSS 22.0 (Statistical Package for Social Sciences, SPSS Inc. Chicago, IL). Data are presented as median, minimum and maximum values. Shapiro-wilk test was used to evaluate normality of parametric values. And the T test was used for the parametric comparison of two independent groups. Man Whitney U test was used for nonparametric comparison of plural, independent groups. Additionally, nonparametric evaluation of binary, independent groups was calculated by Kruskal Wallis test. P value was set at <0.05.

Result

In total, there were 50 celebrities in the study group and 50 volunteers in the control group, and both groups included 35 females and 15 males. The mean age of the volunteers (37.02 years; range: 18–55 years) was similar to that of the celebrities (37.32 years; range: 16–57 years).

In terms of the Westmore criteria distance differences between the celebrities and volunteer groups were not statistically significant. In between-group p-values A–B, B–C, A–C and D–E parameters were 0.277, 1.00, 0.158 and 1.00, respectively for female and 0.876, 1.000, 0.158, 0.132 respectively for male (Table 2). The assessment done using the McKinney measurements (F-G and G-H parameters) revealed that the G–H distance was significantly greater in the famous group than in the volunteer group (females, p=0.031; males, p=0.001). Although the mean F–G value in the famous group (6.26 cm, IPD standardized) was greater than that in the volunteer group (5.93 cm, IPD standardized), the difference was not statistically significant.

Comparison of eyebrow measurements between male and female volunteers revealed significant differences in the Westmore parameters (A–B, p=0,007; B–C, p=0.016; D–E, p=0.000; Table 3). Furthermore, analysis of eyebrow position on the upper face (F–G and G–H) revealed that the G–H parameter was significantly higher in females than in males (p=0.007), and the mean F–G value in females (6.19 cm, IPD standardized) was greater than that in males (5.87 cm, IPD standardized).

Discussion

The notion of an "ideal" eyebrow has changed over time and is influenced by current fashion trends, age, sex, culture and ethnicity. Over the past 50 years, several studies have analyzed eyebrow shape and position to determine the characteristics of the ideal eyebrow. Westmore proposed a model for deriving the ideal brow in 1974 (Fig. 1) [56] , which has been modified over the years. In 1989, Cook et al. [58] argued that the arch above the lateral limbus produced an unnatural,

"surprised" look and proposed that the arch should lie more laterally above the lateral canthus. In 1991, McKinney et al. [57] suggested that other periorbital features and the position of the brow should be considered in determining the ideal eyebrow. They found that the normal distance from the midpupil to the upper edge of the eyebrow was 2.5 cm and the average distance from the upper edge of the eyebrow to the hairline was 5 cm (Fig. 2). In a further modification of the Westmore model, Gunter et al. [59] proposed that a gentle arch should lie somewhere between the lateral limbus and the lateral canthus, and that the lateral brow should be higher than the medial brow. Similarly, in a study comparing the eyebrows of 100 fashion models with those of randomly selected volunteers, Roth et al. [60] found that the eyebrow arch was lateral to the lateral limbus and just medial to the lateral chantus, and that the medial brow was lower than the lateral brow in the horizontal plane. More recently, Baker et al. [1] investigated the importance of face shape in determining facial aesthetics. They compared classically described ideal eyebrows and modified eyebrows in the four basic face shapes (oval, square, long and round) and concluded that face shape may influence the desired outcome and should be considered before eyebrow surgery. However, there is no uniform definition of the ideal brow shape and position.

We found that the mean distance between the brow apex and the lateral limbus (D–E parameter) was greater in the celebrities and fashion models (females, 1.08 cm; males, 0.83 cm, IPD standardized) than in the randomly selected volunteers (females, 1.00 cm; males, 0.59 cm; IPD standardized, Table 2). Similarly, the mean distance between the midpupil and the top of the brow (F–G parameter) was greater in the famous group than in the volunteer group (p=0.031 for females and p=0.001 for males; Table 2). This finding accord with the fact that several cosmetic procedures, including facial makeup, tweezing, tattooing, botulinum toxin and surgical lifting, aim to accentuate the eyebrow arch. Currently, botulinum toxin injections are used to elevate the brow apex and increase the distance between the midpupil and eyebrow [61].

Table 1: List of celebrities and famous people considered to be attractive

1. SCARLET JOHANSSON	26. GEORGE CLOONEY
2. ANGELINA JOLIE	27. ANDRE BANKOFF
3. ADRIANA LIMA	28. IAN SOMERHOLDER
4. BURCU ESMERSOY	29. RICHARD GERE
5. AZRA AKIN	30. JUDE LAW
6. MEGAN FOX	31. MERYEM ÜZERLI
7. JESSICA ALBA	32. MARION COTILLARD
8. CHARLIZE THERON	33. LEIGHTON MEESTER
9. MILLA JOVOVICH	34. MARCELA GUIRADO
10. MONICA BELLUCI	35. KATE WINSLET
11. EVA MENDES	36. ALISON BRIE
12. TYRA BANKS	37. ALEXANDRA DADDARIO
13. KEIRA KNIGHTLEY	38. VANESSA HESSLER
14. AISHWARYA RAI BACHCHAN	39. MEAGAN TANDY
15. NATALIE PORTMAN	40. GABRIELLA WILDE-INGILTERE
16. RACHEL HURD WOOD	41. HOLLY EARL
17. JENNIFER LAWRENCE	42. LISA TOMASCHEWSKY
18. EMILY DIDONATO	43. EMMA STONE
19. SIENNA MILLER	44. TAMSIN EGERTON
20. NICOLE KIDMAN	45. EMMA WATSON
21. BRAD PITT	46. SIMON BAKER
22. KIVANÇ TATLITUĞ	47. ROBERT PATTISON
23. TOM CRUISE	48. LIAM HEMSWORTH
24. DAVID BECKHAM	49. JOSH DUHAMEL
25. ELVIS PRESLEY	50. MAXI IGLESIAS

Table 2: The comparison of the eyebrow shape and position measurements of celebrities and volunteers. (All the measurements are in cm and IPD standardized)

Measurements demonstrating eyebrow shape & position	Famous Female Group (mean(min-max)) n=35	Volunteer Female Group (mean (min-max)) n=35	P value	Famous Male Group (mean (min-max)) n=15	Volunteer Male Group (mean (min-max)) n=15	P value
A-B	5.92(5.08+6.93)	6.21(4.95+8.05)	0.277	5.57(4.97+6.26)	5.78(5.27+7.06)	0.876
B-C	5.00(4.43+6.52)	5.29(4.23+6.14)	1.000	5.59(4.61+6.35)	5.41(5.04+5.84)	1.000
A-C	7.74(7.20+9.10)	8.00(6.80+9.90)	0.158	7.80(7.20+8.40)	7.90(7.50+8.90)	0.158
D-E	1.08(0.72+1.82)	1.00(0.66+1.80)	1.000	0.83(0.61+1.17)	0.59(0.30+0.85)	0.132
F-G	6.28(3.26+7.59)	6.10(4.49+7.84)	0.098	6.19(5.15+8.80)	5.56(4.14+8.02)	0.098
G-H	2.69(2.20+3.61)	2.43(1.81+2.91)	0.031	2.52(2.16+3.29)	1.94(1.54+2.34)	0.001

Table 3: The comparison of the eyebrow shape and position measurements of male famale groups. (All the measurements are in cm and IPD standardized)

	A-B	B-C	A-C	D-E	F-G	G-H
Male (n=30) mean (min-max)	5.67 (4.97-7.06)	5.50 (4.61-6.35)	7.85 (7.20-8.90)	0.71 (0.30-1.17)	5.87 (4.14-8.80)	2.23 (1.54-3.29)
Female(n=70) mean (min-max)	5.65 (4.95-8.05)	5.15 (4.23-6.52)	7.87 (6.80-9.90)	1.04 (0.66-1.82)	6.19 (3.26-7.84)	2.56 (1.81-3.61)
P value	0.007	0.016	0.723	0.000	0.127	0.007

mean (min-max): mean (minimum-maximum)
A-B: The distance from the medial aspect of the eyebrow to the ala
B-C: The distance between the medial and lateral ends of the brow
A-C: The distance between the lateral end of the brow and ala
D-E: The distance between brow apex and lateral limbus
F-G: The distance of forehead
G-H: The distance between midpupil and the top of the brow

The ideal brow shape and position differs between males and females. In males, the eyebrows sit at the level of the upper orbital rim in the horizontal position, whereas female eyebrows sit several millimeters above the orbital rim and have an arch peaking at the apex of the brow [62]. In our study, the height of the brow apex (D–E) and distance between the midpupil and eyebrow (G–H) were significantly greater in females than in males (p=0.000 and p=0.007, respectively; Table 3). Among the celebrities, Angelina Jolie had the highest brow apex (D–E, 1.73 cm). Moreover, the eyebrow length (B–C) and nasal ala to brow (A-B) distance were significantly greater in males than in females (p=0.016 and p=0.007, respectively; Table 3). Conversely, the mean female forehead height (F–G, 6.19 cm, IPD standardized) was higher than that of males (5.87cm, IPD standardized). Moreover, the mean forehead width in the famous group (mean 6.25 cm, IPD standardized) was greater than that in the volunteer group (mean 5.93 cm, IPD standardized). Brad Pitt had the highest forehead in the study (8.8 cm, IPD standardized). The influence of forehead width on the perception of beauty is controversial; however, several studies have concluded that the upper third of the face has the most significant effect on the perception of attractiveness [63].

Literature shows that the face shape is also important in determining the ideal eyebrow shape [62].
Our subanalysis of celebrity eyebrows was supporting the literature, we saw that more rounded eyebrows were ideally suited to round faces (e.g. Adriana Lima), whereas more curved eyebrows were better suited to square faces (e.g. Angelina Jolie). Asymmetric eyebrows are considered normal as long as the difference is not too great [62]. Among the models in our study, Aishwarya Bachchan had the most asymmetric eyebrows; however, that has not prevented her from being described as 'the most beautiful woman in the world'.

For further studies, in order to have more accurate measurement results a metric ruler can be located close to brows before taking photographs and improving number of samples can provide more detailed information for comparison of brow ratios.
In order to improve the analysis results further studies would be performed using more subjects for volunteers and celebrities, also measurements would be applied on subjects using a ruler to get more accurate comparisons.

In conclusion, no single eyebrow shape or position is considered beautiful on every face. Therefore, to obtain the optimal outcome, the cosmetic surgeon should perform a complete facial analysis of the patient's eyebrow, forehead and face shape before surgery, keeping in mind the sex differences in eyebrow shape. The success of eyebrow surgery depends on the surgeon's knowledge of the various brow shapes and positions and the ability to match those to particular face shapes.

References:

1. Baker SB, Dayan JH, Crane A, et al, The influence of brow shape on the perception of facial form and brow aesthetics. Plast Reconstr Surg 2007; 119: 2240-7.

2. Sclafani AP, Jung M, Desired position, shape, and dynamic range of the normal adult eyebrow. Arch Facial Plast Surg 2010; 12: 123-7.

3. Pham S, Wilhelmi B, Mowlavi A, Eyebrow peak position redefined. Aesthet Surg J 2010; 30: 297-300.

4. Berneburg M, Dietz K, Niederle C, et al, Changes in esthetic standards since1940. Am J Orthod Dentofacial Orthop 2010; 137(4): 450.

5. https://www.mensfitness.com/life/entertainment/30-hottest-photos-scarlett-johansson

6. https://www.vanityfair.com/style/2016/06/angelina-jolie-brad-pitt-children

7. http://www.instyle.com/news/adriana-lima-abs-leather-top-nyfw

8. http://www.marieclaire.com.tr/10-soruda-burcu-esmersoyun-bakim-sirlari/

9. http://www.milliyet.com.tr/azra-akin/

10. https://thatnordicguy.deviantart.com/art/Megan-Fox-Angelina-Jolie-538363841

11. http://www.hurriyet.com.tr/iste-altin-kelebek-in-cilegi-jessica-alba-26407468

12. https://www.biography.com/people/charlize-theron-9542564

13. http://celebrityinside.com/film-tv/actresses/milla-jovovich-favorite-color-music-food-movie-perfume-net-worth-biography/

14. http://variety.com/2017/film/asia/mumbai-festival-to-honor-monica-bellucci-1202559987/

15. http://www.instyle.com/celebrity/transformations/eva-mendes-changing-looks

16. http://people.com/style/6-beauty-rules-tyra-banks-lives-by/stick-to-a-regimen

17. https://en.wikipedia.org/wiki/Keira_Knightley

18. https://en.wikipedia.org/wiki/Aishwarya_Rai

19. http://www.instyle.com/news/natalie-portman-beauty-talk-interview-june-2015

20. http://www.sinematurk.com/kisi/18931-rachel-hurd-wood/fotograflar/

21. http://www.elle.com/culture/celebrities/a13032602/jennifer-lawrence-harassment-hollywood/

22. https://www.famousbirthdays.com/people/emily-didonato.html

23. http://www.marieclaire.co.uk/news/celebrity-news/sienna-miller-s-role-has-been-cut-from-black-mass-51118

24. https://dailypost.in/news/entertainment/love-story-tom-cruise-sudden-says-nicole-kidman/

25. http://www.foxnews.com/entertainment/2017/05/15/brad-pitt-talks-sober-life-post-angelina-jolie-split-ive-got-no-secrets.html

26. https://tr.pinterest.com/udayalsindi/kivanc-tatlitug/

27. http://www.imdb.com/name/nm0000129/

28. https://www.famousbirthdays.com/people/david-beckham.html

29. http://time.com/4894995/elvis-in-the-heart-of-america/

30. http://www.parismatch.com/People/George-Clooney-Je-ne-voulais-pas-donner-a-mes-enfants-un-de-ces-ridicules-prenoms-hollywoodiens-1342112

31. https://alchetron.com/Andr%C3%A9-Bankoff

32. http://www.wildaid.org/people/ian-somerhalder

33. https://www.biography.com/people/richard-gere-9309229

34. https://www.famousbirthdays.com/people/jude-law.html

35. https://www.osobnosti.cz/meryem-uzerli.php

36. http://www.instyle.com/celebrity/marion-cotillard

37. https://tr.pinterest.com/pin/343258802822403204/

38. http://www.gettyimages.com/photos/marcela-guirado3

39. http://people.com/movies/kate-winslet-recalls-being-bullied-as-a-kid/

40. www.zimbio.com/photos/Alison+Brie/

EVALUATION OF THE EFFECTS OF SURGICAL ASSISTED MAXILLARY EXPANSION ON THE INCISIVE CANAL

Running title: EVALUATION OF THE EFFECTS OF SURGICAL ASSISTED MAXILLARY EXPANSION ON THE INCISIVE CANAL

Neşet AKAY[1], Umut TEKİN[2], Ercüment ÖNDER[2] , İ.Doruk KOCYİGİT[2] , Fethi ATIL[2]
[1]Department of Oral and Maxillofacial Surgery, Faculty of Dentistry, University of Abant Izzet Baysal, Bolu, Turkey
[2]Department of Oral and Maxillofacial Surgery, Faculty of Dentistry, University of Kirikkale, Kirikkale, Turkey

ABSTRACT

Abstract: The maxillary incisive canal is an important structure in diagnosis, preoperative planning, and prosthetic preparation . The aim of this study was to examine the effects of surgically assisted rapid maxillary expansion (SARME) to evaluate the morphological changes occurring in the length of incisive foramen diameter (IFD), mediolateral transverse of incisive foramen (MTIF) and incisive canal length (ICL) with Cone Beam Computed Tomography (CBCT).
Method: For all patients, CBCT data were obtained before the treatment, and 3 months after the operation. Preoperative and postoperative CBCT images were analyzed in sagittal and axial sections. Preoperative and postoperative changes in the length of IFD, MTIF, and ICL were compared on the CBCT. Results divided into groups according to gender differences.
Result: As a result of this study, it is determined that postoperative IFD, MTIF, ICL values were significantly different compared to preoperative values. ($p < 0.05$)
Conclusion: Incisive foramen and incisive canal changes can occur after SARME. For this reason, those possible changes should be kept in mind before surgical planning, diagnostic definitions, and prosthetic guidance.

Keywords: Cone Beam Computerize Tomography, Incisive Canal, SARME

ÖZET

Özet: Maksiler insiziv kanal ; teşhis, preoperatif planlama ve çene protez hazırlığında önemli bir anatomik yapıdır. Bu çalışmanın amacı, insiziv foramen çapı (IFÇ), insiziv foramen mediolateral transvers yönü (IFMT) ve insiziv kanal uzunluğunda (IKU) cerrahi destekli hızlı maksiller genişlemenin (CDHMG) meydana getirdiği morfolojik değişiklikleri Konik Işın Bilgisayarlı Tomografi (KIBT) ile araştırmaktır.
Yöntem: Tüm hastalar için tedaviden önce ve operasyondan 3 ay sonra KIBT verileri elde edildi. Ameliyat öncesi ve sonrası KIBT görüntüleri sagital ve aksiyal kesitlerde analiz edildi. Ameliyat öncesi ve sonrası IFÇ, IFMT ve IKU uzunluklarındaki değişiklikler KIBT verileri üzerinden karşılaştırıldı. Sonuçlar cinsiyet farklılıklarına görede gruplar arası değerlendirildi.
Sonuç: Bu çalışmanın sonucunda ameliyat sonrası IFÇ, IFMT, IKU değerlerinin ameliyat öncesi değerlere göre anlamlı derecede farklı olduğu belirlendi ($p < 0.05$).
Tartışma: CDHMG'den sonra insiziv foramen ve insiziv kanal değişiklikleri meydana gelebilir. Bu nedenle, bu olası değişikliklere cerrahi planlama, diagnostik tanımlamalar ve çene protez rehberliği öncesinde dikkat edilmelidir.

Anahtar Kelimeler: Koni Işınlı Bilgisayarlı Tomografi, İnsiziv Kanal, SARME

Corresponding Author: Neşet AKAY

Adress: Abant Izzet Baysal University Faculty of Dentistry Department of Oral and Maxillofacial Surgery, Bolu, Turkey
Email address: nesetakay@gmail.com

Introduction

The incisive canal (IC), or nasopalatine canal, is a structure present in the midline of the bilateral maxilla. The incisive canal is located in the posterior of the incisor teeth roots. The incisive foramen (IF) is an oval-shaped opening that faces the posteroinferior side of the palate but the location varies from just above the crest of the alveolar ridge to the level of the apices of the central incisors (1). Incisive canal includes nasopalatine nerve, connective tissue, adipose tissue, minor salivary glands and the terminal branch of the nasopalatine artery. The maxillary incisive papilla is an important anatomical structure in dentistry as it helps to ensure the proper arrangement and alignment of administration of local anesthesia to the midline of the anterior maxillary ridge in the anterior palate (2).
Treatment approach of skeletal maxillary transverse deficiency necessitates the segments to be repositioned in a wider transverse dimension. However, transverse maxillary expansion is considered as the least stable surgical procedure for the correction of dentofacial deformities (3).

Skeletal and dental effects of surgically assisted rapid maxillary expansion (SARME) with either tooth- borne or bone-borne expansion have been widely described in the literature (4). In general, previous studies mainly investigated the effects of SARME separately (5) or focused on direct or indirect effects on maxillary, mandibular, nasal cavity and mucosal constructions (6). The effects of tooth-borne and bone-borne SARME on incisive channels have not yet been sufficiently compared. Studies of maxillary anatomical morphology variations after surgery can affect the treatment management.

In recent years, the need for radiological identification of anatomic structures has become more important and optimal image quality of vital structures has many benefits for both the patient and the clinician especially when surgery is the point at the issue. CT has enabled 3D assessment of the craniofacial structures; CT is also available as a diagnostic tool for the head and neck region (7) and is performed prior to some oral surgical procedures. In most of the studies by Liang X et al, it was found that the image quality of Conical Beam Computed Tomography (CBCT) was comparable or even higher than the other three dimensional systems (8). Coupled with low radiation dose and short scanning time, CBCT system can play a vital role in the diagnosis of hard tissue structures of the dental-maxillofacial region. CBCT is a valuable imaging modality for determining canal morphology and dimensions before surgery. It seems that evaluation of canal location and its dimensional properties using CBCT can provide detailed information that is useful in clinical situations (9) In this respect, knowing the detailed anatomy of IC is essential.

A better knowledge of the neurovascular structures and anatomic variations of the region may facilitate the identification of appropriate surgical techniques (10). Changes in the incisive canal after surgical rapid maxillary expansion should be assessed and it should be evaluated in the future diagnostic procedures and prosthetic planning. The occurrence of significant changes in anatomic points with the SARME method will be important in surgical interventions that may be planned for the same region. These structures are very important to avoid complications during surgery and the following treatment. The aim of this study is to evaluate the morphological changes occurring in the length of incisive foramen diameter (IFD), mediolateral transverse of incisive foramen (MTIF) and incisive canal length (ICL) in patients undergoing SARME with CBCT.

Materials and Method

Thirty consecutive, non-syndromic, Turkish adult patients (mean age * years, range 15–30 years; 15 males, 15 females), with no previous history of craniofacial injury or operation and requiring transverse maxillary expansion were included in this prospective study.
Informed consent was obtained from all the participants. All the patients presented with a reduced maxillary width with posterior unilateral or bilateral cross-bite, with or without anterior dental crowding. Patients who were diagnosed with maxillary transversal insufficiency after orthodontic analysis and clinical examination were included.

The following landmarks were selected for analysis of the sagittal and axial CBCT images; all measurements in mm CBCT slice. CBCT images were obtained before surgery and 3 months after the SARME operation. The study protocol was carried out in accordance with the

principles defined in the Helsinki Declaration including all the arrangements and revisions.

The protocol of this study was approved by the Ethics Committee for Clinical Investigations of Kirikkale University, Kirikkale, Turkey with the file number and date of 08.02/06.03.2014.

Treatment Protocol

Surgical technique: The precise surgical technique and specific types of distractors used during the original study were described by Koudstaal et al. (11). The same surgical procedure was applied to all patients. Briefly, osteotomy at the level of Le Fort I, with additional midline osteotomy and without pterygomaxillary disjunction, was performed under general anesthesia (12).
Orthodontic treatment and expansion; Trans-palatal retractor was placed between the deepest point of the palate and first molar in 13 patients by using trans-palatal distractor appliances (Transpalatal Distractor, Synthes, Oberdorf, Switzerland). Activation of the device initiated 5 days after the operation. The screws were activated twice a day with 0.33mm (2x0,33mm=0.66mm) until to the lingual tubercles of the superior premolar and molar teeth came together with the buccal tubercles of the lower molar and premolars.
Hyrax appliances (Dentarum, Ispringen, Deutschland) were used in 17 patients. It was activated in the oral cavity 5 or 7 days after the operation. The patient was told to activate the dilatation screw twice daily (2x0,2=0.4 mm) and to continue until the palatinal tubercles of the molar teeth reach to the lower buccal tubercle.

Radiological method: PBC Uni3D (Vatech, Seoul, Korea) device was used for CBCT scans. DICOM format images of the patients were obtained after transferring the CBCT to Ez3D Plus (Vatech, Hwaseong-si, Korea) program. Images with a cross-sectional thickness of 0.2 mm were combined by a computer program (EZ3D) to obtain data. Images in the NewTom 3G (Newtom, Verona, Italy) system software was exported to the 512 x 512 Matrix Digital Imaging and Communications in Medicine (DICOM) file format to work with the Anatomage (Almaden Blvd, San Jose, USA) software.
Changes in the IFD, MTIF, and ICL were compared in the same preoperative and postoperative sections, and measurements were obtained by CBCT distance measurement (male and female).
Reference points below are used to standardize the measurements

1- IFD; the dimensions of the nasopalatine canal were measured in millimeters using the reformatted sagittal CBCT images. The following landmarks were selected to standardize the measurements. IF was measured at the oral entrance of the canal (Fig 1).

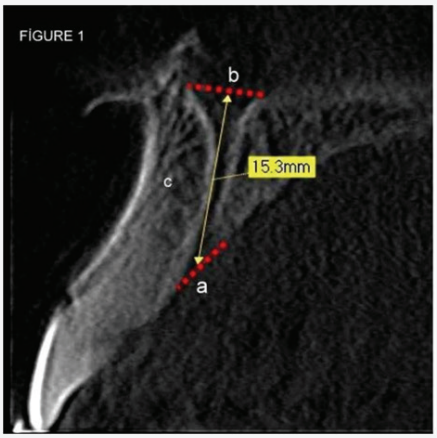

Figure 1. The sagittal section shows the measurements of the length of the nasopalatine canal and the anteroposterior diameter of the canal at the nasal fossa, mid-level, and hard palate. Measurements of the incisive foramen, nasopalatine foramen and incisive canal length on sagittal section CBCT; a) The diameter of the incisive foramen., b) the diameter of the nasopalatine foramen, c) The length of the nasopalatine canal

2- ICL; The canal's diameter was measured at the midpoint between these two levels. (Fig 1) Bornstein and his friends' criteria (13) was taken as reference when determining incisive canal's length and angle. The distance from the opening of incisive foramen to hard palate and to the nasopalatine canal where it opens to the nasal floor was measured. Angled incisive canals were measured separately and the sum was determined. (Fig2)

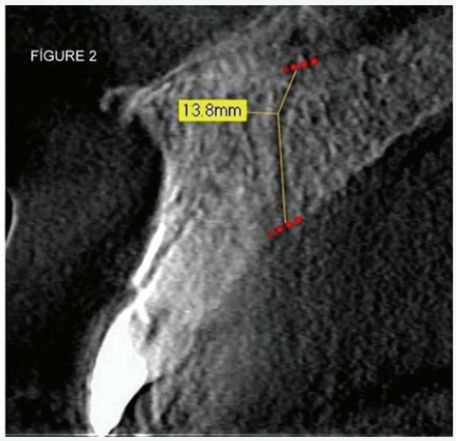

Figure 2. An axial section at the level of the incisive fossa shows the mediolateral diameter of the incisive fossa. Measurement of the length of the angled incisive canal on sagittal section CBCT

3- MTIF; The medio-lateral transposition of the incisive foramen to midline has been determined by the angle between the linear distance from the incisive foramen to the spinal nasalis posterior (PNS) and the midline.(Fig3)

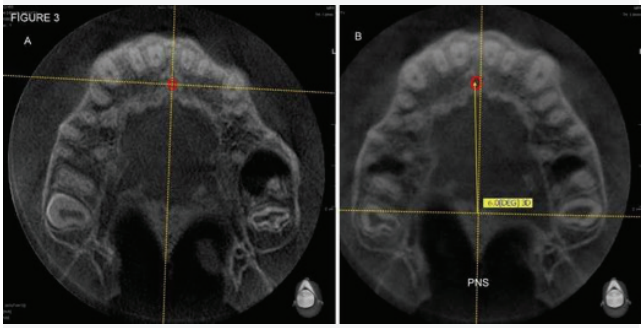

Figure 3. The amount of incisive foramen displacement was calculated by measuring the angle of the linear line drawn by the spinal nasalis posteriorly from the center of the incisive foramen.a) Preoperative CBCT view of the linear angle incisive foramen's center makes with PNS b) CBCT view that shows postoperative transposition of incisive foramen

Statistical analysis:

All data were analyzed using the non-parametric Mann-Whitney U tests to evaluate statistical significance between the groups. And Wilcoxon sign test was used compare the means within the groups. A significance level of p-value was determined as 0.05. All the statistical analysis was performed using SPSS for Windows, release v.20 (SPSS, Chicago, IL)

Result

IFD

Preoperative and postoperative comparisons of IFD were evaluated with Wilcoxon Sign Test. IFD changes were found to be statistically significant ($p < 0.05$) postoperatively comparing the groups without distinction (Table1). When the preoperative incisive foramen diameter values were evaluated in general the minimum diameter was 2 mm ± 0.5 while the maximum diameter value was 5.4 mm ± 0.5 and the mean value was evaluated as 3.6 mm ± 0.5. Postoperative measurements of these measurements were as follows; minimum 3.5 mm ± 0.5, maximum 5.4 mm ± 0.5, and mean 4.5 ± 0.5 mm.There was no significant difference in between genders but the average values measured in males were higher than women.

Table 1: IFD

Preoperative and Postoperative Comparisons of Incisive Foramen Diameter with Wilcoxon Sign Test

PARAMETERS							Wilcoxon Sign Test	
	N	Mean	Median	Min.	Max.	Sd	Z	P
IFD (Preoperative)	30	3,6	3,7	2,0	4,5	0,5	-4,2	*0,0001
vIFD (Postoperative)	30	4,1	4,0	2,5	5,4	0,6		

(p <0.05)*

MTIF

Preoperative and postoperative comparisons of MTIF were evaluated with Wilcoxon T-test. There was no statistically significant difference between the left and right mediolateral changes. However, the change in the right direction was statistically significantly higher when compared patients with no directional change patients.($P < 0.05$) (Table 2) Mediolateral transverse of incisive foramen was observed in 13 patients, 8 of the patients had a left side direction change and 5 of the patients had a right side direction change. There was no significant difference in between genders group.

Table 2 : MTIF

Comparison with MTIF Wilcoxon T-test

	PARAMETER						Wilcoxon T Test	
Deviation	N	Mean	Median	Min.	Max.	Sd	Z	P
Right	8	1,9	2	1,1	3	0,664	-0,105	*0,200
Left	5	1,8	1,9	1,6	2	0,622		
Non	17	1,2	1,1	0,4	2,5	0,612	-0,257	0,024

(p <0.05)*

ICL

Preoperative ICL was 14.6±0,5 mm and postoperative ICL was15,2±0,5 mm The differences between post and preoperative values were statistically significant. The postoperative length of the incisive canal was significantly higher than the preoperative length in the group of male patients. There was no significant difference in comparison of the age groups with the Mann Whitney U test .(0,05)

Table 3: ICL

The change of ICL compareted with Wilcoxon Sign Test

PARAMETER						Wilcoxon Sign Test		
	N	Mean	Median	Min.	Max.	Sd	Z	P
ICL (Preoperative)	30	12,7	12,5	11,2	14,6	1,0	-4,8	*0,0001
ICL (Postoperative)	30	13,2	13,0	11,8	15,2	1,1		

*(*p<0.05)*

Discussion

During the cranial formation, structures' growths and developments are connected to each other. Growth processes that share the same wall affect each other while different components ossificate; they form various size, shape, and positions. Studies that explain the morphology of incisive canal have emphasized the incisive canal pathologies(14). Different studies have indicated that matters like age, gender and ethnicity can cause variations in the radius of incisive foramen (15).

The existence of a neurovascular structure at the anterior maxillar region increases the risk of complications. Due to the injury of this neurovascular structure; hyperesthesia, paresthesia or pain can occur and affect patient's life quality (10). The surgery caused neurovascular injuries in the incisive canal may even cause massive hemorrhage in maxillary sinus (16). Resorption of alveolar bone, incisive canal and incisive foramen's variations of size and location can cause limitations during surgery. These anatomical limitations of the incisive foramen and incisive canal can restrict ideal positioning of the implant (17). Studies about size, morphology and anatomical variations of the canal have increased recently because of these findings.

Neurosensorial injury, pain, and hemorrhage are frequent complications of maxillar surgeries(23). Also, the implants that are in touch with neural tissues have been reported to complicate osseous integration.(13)Saying that radiographic evaluations and detailed surgical planning are important for the prevention of complications. Innovations in imaging methods provided a closer and detailed examination of structures such as the incisive canal, foramen mentalis, mandibular canal possible. High quality, low dosage, and low costs have increased the use of CBCT in recent studies (15). Different imaging systems have been used in various studies relating SARME (17). In our study, CBCT images were evaluated by one researcher and it was observed that incisive foramen and incisive canal may individually vary; also after SARME, such morphologic variations can increase. It has been observed that the incisive foramen width being less than 6 mm or greater than 10 mm could be possibly pathological.Although Etoz and Şişman (19) have reported that IF(p=0.001) amplitude shows that there's a significant difference between men and women; Lopez, Jornet and his friends (20) found lower results than Etoz et.al indicating there is no significant difference in gender. Such a difference may be attributed to the sample size the study or the differences of the study population.

Although there was no significant difference in between genders in our study, the mean values measured in males were higher.

Mardinger and his friends (21) have reported an increase in incisive canal width after tooth extraction but this hypothesis wasn't supported by Güncü (21).
In the study of Liang (22)the findings were consistent with Mardinger(24) and our study, the IFD showed a statistically significant difference after SARME. The mean of the IFD was measured as 3.6 mm ± 0.5 preoperatively. The postoperative mean was 4.5 ± 0.5 mm in the study. On patients that have been evaluated postoperatively, the changes that occurred compared to preoperative period was found to increase and it was a statistically significant change ($p < 0.05$).

Since there was no study related to MTIF, we could not compare our results. In our study, we observed that there was a change towards the mediolateral direction due to the increased amount of enlargement.
In the studies which ICL was evaluated according to gender (21,6,13), ICL was found significantly higher in males, and in some studies [23,15] it was stated that females' values were higher.

In addition, it was noted that the incisive canal length may differ between individuals in different countries (18). In our study, regardless of groups, the average change in ICL was 12.5 mm in the preoperative evaluation and 13 mm in the postoperative evaluation. When considering gender's effect on ICL, it was seen that men had significantly greater values. In our study, ICL (Preoperative) and ICL (postoperative) values were significantly higher in males when compared to females. However, Song et. al. (6) reported that the length of the incisive canal did not change with aging, but the incisive canal length was showing differences with the loss of central incisor tooth and the incisive canal length was significantly longer in the anterior edentulous patients.

Some authors have also addressed the effect of age and gender on the length and width of the incisive canal [21]. While the diameter of the incisive canal is increasing due to the atrophic maxilla, incisive canal length decreased. In our study, there was no significant difference in the incisive canal sizes of our patients in different age groups. Hence our patient group was consisting the young population, we believe that there is no impact of age on our results of incisive canal length.

When we look at the studies, we can see that incisional canal morphology can change; and gender and edentation are particularly influential factors. In the review of the literature, we have seen studies on the change of the morphology and the morphometric variations of the incisive canal(24) after SARME(25). However, there is a need for some additional data on maxilla hence there are only a few studies examining the anatomical, morphological and oro-facial changes on the maxilla.
The purpose of this prospective study was to determine the incisive canals and incisive foramen effects of SARME and to compare these effects among groups using the CBCT system.

Conclusion

As a result of our study, a statistically significant change in the diameter, length, and direction changes structure of the incisive canal contributed to the studies on morphological changes that would occur after SARME. We think this should be evaluated carefully in the pre-maxillary area for surgical procedures, diagnosis, and prosthetic preparation. After SARME, we think that the changes that will occur in the anterior bone structures of the maxillary can contribute to the results that are supported by different studies.

References

1. Sarandha DL, Hussain ZU Textbook of Complete Denture Prosthodontics. Jaypee Brothers, Medical Publishers, 2008

2. Scheid RC, Woelfel JB Woelfel's Dental Anatomy: Its Relevance to Dentistry. Lippincott Williams & Wilkins, 2007

3. Drake R, Vogl AW, Mitchell AWM, Gray's Anatomy for Students. Elsevier Health Sciences, 2009

4. Ghom AG, Normal Radiographic Anatomy. In: Ghom A.G. eds., Textbook of Oral Radiology. New Delhi: Elsevier 2008; 191–212.

5. Glickman GN, Preparation for Treatment. In: Cohen S.,

Burns R. C. eds., Pathway of the Pulp. St Louis: Mosby 2002; 77–109.

6. Song WC, Jo DI, Lee JY, Kim JN, Hur MS, Microanatomy of the incisive canal using three dimensional reconstruction of micro CT images: an ex vivo study. Oral Surg Oral Med Oral Pathol Oral Radiol Endod 2009; 108:583-590.

7. Jain NV, Gharatkar AA, Parekh BA, Musani SI, Shah UD , Three-Dimensional Analysis of the Anatomical Characteristics and Dimensions of the Nasopalatine Canal Using Cone Beam Computed Tomography. J Maxillofac Oral Surg. 2017 ;16(2):197-204.

8. Liang X, Jacobs R, Corpas LS, Semal P, Lambrichts, Chronologic and geographic variability of neurovascular structures in human mandible. Forensic Sci Int 2009; 190:24–32

9. Rodricks D, Gupta A, Phulambrikar T, Singh SK, Sharma BK, Agrawal P. Mymensingh Anatomical and Morphological Characterization of the Nasopalatine Canal: A Cone-Beam Computed Tomography Study. Med J. 2016 ;25(2):349-56.

10. Jacobs R, Lambrichts I, Liang X, Martens W, Mraiwa N,Neurovascularization of the anterior jaw bones revisited using high-resolution magnetic resonance imaging. Oral Surg Oral Med Oral Pathol Oral Radiol Endod 2007; 103: 683–693.

11. Koudstaal MJ, Poort LJ, Van der Wal KG, Wolvius EB, Prahl Andersen B, Schulten AJ. Surgically assisted rapid maxillary expansion (SARME): a review of the literature. Int J Oral Maxillofac Surg. 2005; 34(7):709-14.

12. Filippi A, Pohl Y, Tekin U, Sensory disorders after separation of the nasopalatine nerve during removal of palatal displaced canines: prospective investigation. Br J Oral Maxillofac Surg 1999; 37: 134–136

13. Bornstein, M.M, Balsiger R, Sendi P, Von arx T, Morphology of the nasopalatine canal and dental implant surgery: a radiographic analysis of 100 consecutive patients using limited cone-beam computed tomography. Clinical Oral Implants Research 2009; 22(3), 295-301

14. Lieberman, D.E, Mc carthy, R.C , The ontogeny of cranial base angulation in humans and chimpanzees and its implications for reconstructing pharyngeal dimensions. Journal of Human Evolution 1999; 36(5), 487-517.

15. Mraiwa N, Jacobs R, Van Cleynen J, Sanderink G, Schutyser F, The nasopalatine canal revisited using 2D and 3D CT imaging. Dentomaxillofac Radiol 2014; 33:396–402.

16. Hong Y-H, Mun S-K, A case of massive maxillary sinus bleeding after dental implant. Int J Oral Maxillofac Surg 2011; 40:758–760

17. Asaumi R, Kawai T, Sato I, Yoshida S, Yosue T, Three-dimensional observations of the incisive canal and the surrounding bone using cone-beam computed tomography. Oral Radiology 2010; 26: 20– 28.

18. Guncu G.N, Yildirim Y.D, Yilmaz H.G, Galindo-Moreno P, Velasco-Torres M, Al-Hezaimi K, Is there a gender difference in anatomic features of incisive canal and maxillary environmental bone? Clin Oral Implants Res 2013; 24(9):1023–1026.

19. Etoz M, Sisman Y, Evaluation of the nasopalatine canal and variations with cone-beam computed tomography. Surg Radiol Anat 2014; 36(8):805–812

20. Lopez Jornet, Pia, et al. "Morphological characterization of the anterior palatine region using cone beam computed tomography." Clinical implant dentistry and related research 2015; 459-464.

21. Mardinger O, Namani-Sadan N, Chaushu G, Schwartz-Arad DMorphologic changes of the nasopalatine canal related to dental implantation: a radiologic study in different degrees of absorbed maxillae. J Periodontol 2008; 79:1659–1662

22. Liang X, Jacobs R, Martens W, Hu Y, Adriaensens P, Quirynen M, Macro- and micro-anatomical, histological and computed tomography scan characterization of the nasopalatine canal. J Clin Periodontol 2009; 36(7):598–603

23. Liang X, Lambrichts I, Corpas L, Politis C, Vrielinck L, Ma

GW, Jacobs R, Neurovascular disturbance associated with implant placement in the anterior mandible and its surgical implications: literature review including report of a case. Chin J Dent Res 2008; 11:56–64

24. Casado PL, Donner M, Pascarelli B, Derocy C, Duarte MEL, Immediate dental implant failure associated with nasopalatine duct cyst. Implant Dent 2008; 17:169–175.

25. Artzi Z, Nemcovsky CE, Bitlitum I, Segal P, Displacement of the incisive foramen in conjunction with implant placement in the anterior maxilla without jeopardizing vitality of nasopalatine nerve and vessels: a novel surgical approach. Clin Oral Implants Res 2000; 11: 505–510

Complication of revision rhinoplasty: Columella necrosis

REVİZYON RİNOPLASTİ KOMPLİKASYONU: KOLUMELLA NEKROZU
COMPLICATION OF REVISION RHINOPLASTY: COLUMELLA NECROSIS

Burak Mustafa TAŞ[1], Gökçe ŞİMŞEK[2], Ercan AKBAY[3], Burak ERDEN[4], Rahmi KILIÇ[5]
[1]Kırıkkale Yüksek İhtisas Hastanesi Kulak-Burun-Boğaz Kliniği, Kırıkkale, Türkiye.
[2]Kırıkkale Üniversitesi Tıp Fakültesi Kulak-Burun-Boğaz Kliniği, Kırıkkale, Türkiye.
[3]İnova Hastanesi Kulak-Burun-Boğaz Kliniği, Aksaray, Türkiye.
[4]Mersin Şehir Eğitim ve Araştırma Hastanesi Kulak-Burun-Boğaz Kliniği, Mersin, Türkiye.
[5]Ankara Eğitim ve Araştırma Hastanesi Kulak-Burun-Boğaz Kliniği, Ankara, Türkiye.

ABSTRACT

The nose is at the center of facial aesthetics. It is the most interested body part by facial plastic surgeons. There is an increase in revision surgery with septorhinoplasty operations performed frequently by ear-nose-throat doctors. In our case, we presented a male patient who previously had septorinoplasty surgery and applied to our clinic with complaints of nasal obstruction and nasal external deformity. In the physical examination of the patient, operated for septorhinoplasty at the outer center approximately five years ago, a polypropylene suture was seen in the supratip region. Patient underwent revision septorhinoplasty operation, 4-5 mm necrotic area was observed in the columella in the postoperative period. Columella necrosis was repaired with "Rintala flap". In revision rhinoplasty operations, fibrotic changes related to the previous operation should be kept in mind and surgery should be planned accordingly. It should be remembered that secondary operations have a higher risk of complications than primary surgery.

Key Words: Columella; Polypropylene; Revision; Rhinoplasty

ÖZET

Burun yüz estetiğinin merkezindedir. Yüz plastik cerrahları tarafından en çok ilgilenilen organdır. Kulak-burun-boğaz doktorları tarafından sıklıkla yapılan septorinoplasti operasyonları ile birlikte revizyon cerrahisinde artış olmaktadır. Olgumuzda daha önce septorinoplasti ameliyatı geçirmiş ve nazal obstrüksiyon ve nazal eksternal deformite şikayeti ile kliniğimize başvuran bir erkek hastayı sunduk. Yaklaşık beş yıl önce dış merkezde bir septorinoplasti operasyonu olduğunu belirten hastanın fizik muayenesinde, supratip bölgesinde polipropilen bir sütür görüldü. Revizyon septorinoplasti operasyonu yapılan hastaya postoperatif dönemde columella'da 4-5 mm nekrotik alan gözlendi. Columella nekrozu "Rintala flep" ile onarıldı. Revizyon rinoplasti operasyonlarında önceki operasyonla ilgili fibrotik değişiklikler akılda tutulmalı ve yapılacak cerrahi buna göre planlanmalıdır. Hastaya yapılan ikincil operasyonların primer cerrahiye göre komplikasyon riskinin daha yüksek olduğu unutulmamalıdır.

Anahtar Kelimeler: Kolumella; Polipropilen; Revizyon; Rinoplasti

Corresponding Author: Gökçe Şimşek

Adress: Kırıkkale Üniversitesi Tıp Fakültesi Kulak-Burun-Boğaz Kliniği, Kırıkkale, Türkiye
Email address: drgokcesimsek@hotmail.com

Bu olgu sunumu, poster bildiri olarak 16-19 Nisan 2015 tarihinde Antalya'da düzenlenen 11. Türk Rinoloji Kongresinde sunulmuştur.

Giriş

Yüzümüzün merkezinde yerleşmesinden dolayı yüz estetiği açısından önemli konumda bulunan burun, fasiyal cerrahi açısından en çok ilgilenilen organdır. Rinoplasti, bu nedenledir ki, fasiyal plastik cerrahları tarafından en çok uygulanan cerrahi girişimdir (1).

Sıklıkla yapılan rinoplasti operasyonlarının beraberinde getirdiği revizyon cerrahi ihtiyacı gittikçe artmaktadır (1). Artan revizyon rinoplasti operasyonları postop dönemde oluşabilecek komplikasyonlarda artışa neden olmaktadır. Revizyon ameliyatlardaki değişmiş nazal anatomi ve yetersiz destek yapılar bu komplikasyonların nedenleri arasındadır. Nadir olmasına rağmen fizik muayenede kolumellada perfüzyon yetersizliği bulguları görüldüğünde kolumella nekrozu düşünülmelidir. Revizyon rinoplasti operasyonlarında komplikasyon ihtimali daha fazla olmasına rağmen primer rinoplastilerde de komplikasyon açısından dikkatli olunmalıdır (1).

Biz bu vakamızda daha önce rinoplasti olan bir hastanın revizyon cerrahisi sonrası gelişen kolumella nekrozu komplikasyonunu sunmayı amaçladık.

Olgu

Otuz dokuz yaşında erkek hasta kliniğimize burun tıkanıklığı ve burunda kozmetik deformite şikayetiyle başvurdu. Anamnezde hastanın beş sene önce dış merkezde açık teknik septorinoplasti operasyonu olduğu öğrenildi. 2 yıl önce de burun ucunda kızarıklık olduğu ve iltihap aktığı öğrenildi. Günde bir paket sigara içen hastada nazal travma ve ek hastalık öyküsü bulunmamaktaydı.

Hastanın fizik muayenesinde önceki operasyona bağlı kolumellada ve sol medial krus cildinde skar dokusu mevcuttu. Hastada nazal cilt ve ciltaltı dokular fibrotik görünümdeydi. Nazal aksta ve septumda deviasyon ve tip pitozu olan hastanın supratip bölgesine uyan ciltten polipropilen sütür görünüyordu (Resim-1). Hastaya açık teknik revizyon rinoplasti operasyonu planlandı. Operasyon sırasında eski ameliyata bağlı yoğun fibrotik dokular izlendi. Polipropilen sütürler çıkarıldı ve septumdan alınan kıkırdak dorsuma yerleştirildi. Gerginliksiz kapama yapılarak kolumella insizyonu 6/0 polipropilen sütür ile primer sütüre edildi. Postoperatif 1. günde kolumellada renk değişikliği başlayan hastada 3. günde morluk oluştu. Postoperatif 1. Günden itibaren pirasetam (3x1, po), asetilsalisilik asit (100mg 1x1, po), sıcak uygulama tedaviye eklendi. Nekroz gelişen alana günlük debridman, rifampisin ve borik asitli pansuman uygulandı (Resim-2). Kolumellar nekroz gelişen hastaya postoperatif 20. günde yeniden ameliyat planlandı. Operasyonda 4-5 mm'lik nekrotik alan debride edildi ve kolumella nekrozu gerginlik olmayacak şekilde rintala flebi ile onarıldı (Resim-2). Hastaya postoperatif dönemde antibiyoterapi (amoksisilin+klavulanik asit 1gr 2x1, po), asetilsalisilik asit ve pirasetam tedavisi başlandı. Hasta hiperbarik oksijen tedavisine yönlendirildi ancak hasta bu tedaviyi kabul etmedi. Postoperatif dönemi sorunsuz olan hasta takibe alındı (Resim-3)

Resim-1. *a: Nazal aksta devasyon b:Kolumella bölgesinde fibrotik skar görünümü ve önceki operasyonda kullanılan propilen sütürün ciltten yüzeyelleşmesi (ok) c: Pitotik tip ve kolumella cildindeki fibrotik skarın alt yan görüntüsü d: Muayenede çıkarılan propilen sütür.*

Resim-2. *a: Postoperatif 3. gün kolumella cildinde nekroz görüntüsü b: Kolumellar nekroz alanının alt yandan görüntüsü, nekrozun tüm flep boyunca olduğu izleniyor. c: Postoperatif 15. gün kolumella nekroz alanının debridmanlar sonrası görüntüsü d: Postoperatif 20. günde rintala flebi ile onarımın intraoperatif görüntüsü.*

Resim-3: *Postoperatif 1. ay sonraki erken takip görüntüsü.*

Tartışma

Rinoplasti operasyonları görünüm ve fonksiyonu düzeltmek amacıyla yapılan hastaya özgü cerrahi girişimlerdir. Rinoplasti planlanan hastalarda genellikle septum deviasyonu da eşlik ettiği için operasyon 'Septorinoplasti' adını alır. Uygulanan teknikler geliştikçe hastaların ve cerrahın beklentisi artmaktadır.

Rinoplasti operasyonlarında nazal tip bölgesinde kıkırdak şekillendirmek için sıklıkla sütürler kullanılmaktadır. Her cerrah kendi deneyimlerine göre farklı çeşitlerde sütür kullanabilmektedir. Polipropilen yapıdaki sütürler dokuda enflamatuar reaksiyona neden olup yabancı cisim reaksiyonu yapabilirler (2). Yabancı cisim reaksiyonu ve enfeksiyon sonucunda hiperemi ve püy drenajı görülebilir. Özellikle nazal tip bölgesinde yabancı cisim reaksiyonuna neden olabilen polipropilen sütürlerin yerine günümüzde polidioksanon sütürler sıklıkla kullanılmaktadır.

Sigara içiciliği özellikle cilt ile ilgili işlemlerde komplikasyonları arttırmaktadır (3). Kolumella nekrozu gibi iskemik olaylara bağlı gelişen komplikasyonlarda hasta sigara içmeye devam etmemelidir (4,5). Her ne kadar Layliev ve ark.nın (6) yapmış oldukları geniş serili çalışmada sigara içiciliğinin septorinoplasti komplikasyonlarını arttırmadığı belirtilmiş olsa da komplikasyonları önlemek amacıyla rinoplasti operasyonu öncesinde sigaranın bırakılması önerilmektedir.

Septorinoplasti operasyonları sonrasında kolumella nekrozu nadiren görülür. Kolumella nekrozu kapalı teknik rinoplastilerde açık tekniğe göre daha az görülür. Özellikle tip projeksiyonun ve rotasyonun aşırı arttırıldığı olgularda kolumella nekrozu ihtimali artar (5). Revizyon ameliyatlar sonrası oluşan yetersiz doku perfüzyonu komplikasyonlara yol açar (7). Yetersiz doku perfüzyonu sonucunda iskemik alanların erken tanınması komplikasyonlara erken müdahaleye olanak sağlar.

Dokuda iskemik belirtilerin oluşmasından sonra hasta yönetimi ile ilgili yapılacak birkaç önemli adım vardır. Öncelikle gerginliğe neden olan bir bandaj varsa derhal çıkarılmalı, gerginlik önlenmelidir. Doku perfüzyonunu arttırmaya yönelik sıcak uygulama, asetilsalisilik asit, pirasetam gibi mikrodolaşımı düzenleyici medikal tedavi ve hiperbarik oksijen desteği verilmelidir. Yapılan çalışmalarda pirasetamın pediküllü fleplerin yaşam şansını arttırdığı ve özellikle flebin distal kısmında dolaşımı iyileştirdiği bildirilmiştir (8).

Kolumella nekrozunun rekonstrüksiyonunda nazolabial flep, alın flepleri, full-thickness deri greftleri ve kartilaj kompozit greftler kullanılabilir (9). En sık tercih edilen rekonstrüksiyon yöntemi nazolabial fleplerdir (10). Kartilaj defektiyle beraber olan kolumella nekrozunda kartilaj kompozit greftler tercih edilebilir.

Rinoplasti operasyonları gittikçe artan sıklıkta yapılan operasyonlar olduğu için beraberinde komplikasyonlar ve sekonder cerrahi ihtiyacında artma olmaktadır. Postop dönemde oluşabilecek komplikasyonlar genellikle cerrahın deneyimine, hastanın nazal anatomisine ve kullanılan materyale bağlı olmaktadır. Ancak sekonder cerrahilerde bunlara ilaveten, nazal yumuşak doku örtüsünün bozuk oluşu, yetersiz nazal çatı, perioperatif dönemde cerrah ve hasta iletişiminde yetersizlik ve operasyon sonrasında travmatik yaralanmalar komplikasyon riskini daha da arttırmaktadır. Bu da sekonder rinoplasti sonrası hasta memnuniyetini düşürmektedir (11). Bu nedenle revizyon cerrahiler daha fazla dikkat ve bilgi gerektirmektedir (12).

Sonuç

Artan sıklıkta yapılan rinoplasti operasyonları fasiyal estetiği dramatik olarak değiştirdiği için perioperatif dönemde mutlaka hastalar iyi değerlendirilmeli ve takip edilmelidir. Cerrahın başarısı ve hastanın psikiyatrik durumu açısından dikkatli olunması gereken operasyonlar olduğu için uygulanacak işlemler dikkatle düşünülmelidir.

Hastaya yapılacak sekonder ameliyatların komplikasyon açısından daha riskli olduğu unutulmamalıdır. Bunlara rağmen gelişebilecek komplikasyonlara karşı hazırlıklı olunmalı ve hastayla iyi iletişim kurup süreç iyi yönetilmelidir.

Kaynaklar

1. Kamer FM, McQuown SA. Revision rhinoplasty. Analysis and treatment. Arch Otolaryngol Head Neck Surg. 1988;114(3):257-66.

2. Kama NA, Coscun T, Yavuz H, Doğanay M, Reis E, Akat AZ. Autologous skin graft, human dura mater and polypropylene mesh for the repair of ventral abdominal hernias. An experimental study. Eur J Surg 1999;165(11):1080-5.

3. Silverstein P. Smoking and wound healing. Am J Med. 1992;93:22S–24S.

4. Mrad MA, Almarghoub MA. Skin Necrosis following Rhinoplasty. Plast Reconstr Surg Glob Open. 2019;7(2):e2077.

5. Kang IG, Jung JH, Kim ST, Kim YJ. Reconstruction of a columellar defect with a nasolabial island flap. Clin Exp Otorhinolaryngol. 2014;7(2):142–144.

6. Layliev J, Gupta V, Kaoutzanis C, Ganesh Kumar N, Winocour J, Grotting JC, Higdon KK. Incidence and Preoperative Risk Factors for Major Complications in Aesthetic Rhinoplasty: Analysis of 4978 Patients. Aesthet Surg J. 20171;37(7):757-67.

7. Amirlak B, Dehdashtian A, Sanneic K, Lu KB, Cheng J. Unique Uses of SPY: Revision Rhinoplasty. Plast Reconstr Surg Glob Open. 2019;7(6):e2123.

8. Tuncer S, Ayhan S, Findikcioglu K, Ergun H, Tuncer I. Effect of systemic piracetam treatment on flap survival and vascular endothelial growth factor expression after ischemia-reperfusion injury. J Reconstr Microsurg. 2011;27(7):409-18.

9. Sherris DA, Fuerstenberg J, Danahey D, Hilger PA. Reconstruction of the Nasal Columella. Arch Facial Plast Surg. 2002;4(1):42–46.

10. Smith V, Papay FA. Surgical options in columellar reconstruction. Otolaryngol Head Neck Surg. 1999;120947-951

11. Hellings PW, Nolst Trenité GJ. Long-term patient satisfaction after revision rhinoplasty. Laryngoscope. 2007;117(6):985-9.

12. Çağıcı CA, Erkan AN, Yılmazer C, Özer C, Çakmak Ö. Septorinoplasti sonrası dikişe bağlı geç dönem burun ucu enfeksiyonu. KBB ve BBC Dergisi 2007;15:31-6.

Koşuyolu Mah. Ali Nazime Sk. No: 45
Koşuyolu 34718 Kadiköy İstanbul
Telefon : +90 (216) 428 95 51
Faks : +90 (216) 428 95 91
E-posta : info@fpcd.org.tr
Web :www.fpcd.org.tr

ÜYELİK FORMU

Yüz Plastik Cerrahi Derneği Yönetim Kuruluna,
Derneğinize üye olmak istiyorum. Gereğinin yapılmasını saygılarımla arz ederim.

____/____/____

Ad Soyad : _____

İmza: _____

Uzmanlığınızı işaretleyiniz :

Kulak Burun Boğaz Hastalıkları	☐ Asistanı /	☐ Uzmanı
Estetik Plastik ve Rekonstrüktif Cerrahi	☐ Asistanı /	☐ Uzmanı
Dermatoloji	☐ Asistanı /	☐ Uzmanı
Göz Hastalıkları	☐ Asistanı /	☐ Uzmanı

Lütfen üyelik için gerekli olan aşağıdaki bilgileri okunaklı olarak yazınız:

T.C. No : _____
Anne Adı : _____
Baba Adı : _____
Doğum Yeri : _____
Doğum Tarihi : _____
E-mail : _____
Kurum : _____
Cep Telefonu : _____
Adres : _____

Dernek tüzüğüne göre başvurular KBB uzmanı 2 asil üye tarafından desteklenmelidir.
Yüz Plastik Cerrahi Derneği Yönetim Kurulu ilk toplantısında üyelik başvurusunun kabulüne veya reddine karar verir.

Destekleyen Üyeler

Ad Soyad : _____ Ad Soyad : _____

İmza : _____ İmza : _____

TURKFPS

Turkish Journal Of Facial Plastic Surgery

Cilt / Volume:1 | Sayı / Issue:1 | Kasım / November 2020